

Case report

SUPERIOR SAGITTAL SINUS THROMBOSIS IN CHILDHOOD

Aleksandra Gavrilovska-Dimovska¹, Andrea Gavrilovski², Venko Filipce¹¹ University Clinic for Neurosurgery; Ss. Cyril and Methodius University, Faculty of Medicine, Skopje, Republic of North Macedonia² University Clinic for Traumatology, Orthopedics, Anesthesiology, Reanimation and Intensive Care Skopje; Ss. Cyril and Methodius University, Faculty of Medicine, Skopje, Republic of North Macedonia

Abstract

Citation: Gavrilovska-Dimovska A, Gavrilovski A, Filipce V. Superior sagittal sinus thrombosis in childhood - a case report. Arch Pub Health 2021; 13 (1).

doi.org/10.3889/aph.2021.5722

Key words: veins of dural sinus, thrombosis, conservative treatment.***Correspondence:** Gavrilovska-Dimovska Aleksandra. University Clinic for neurosurgery, Skopje, Republic of North Macedonia. E-mail: gavrilovskia@yahoo.com**Received:** 5-Jan-2021; **Revised:** 18-Feb-2021; **Accepted:** 25-fev-2021; **Published:** 20-Jun-2021**Copyright:** © 2021. Aleksandra Gavrilovska-Dimovska, Andrea Gavrilovski, Venko Filipce. This is an open-access article distributed under the terms of the Creative Commons Attribution License, which permits unrestricted use, distribution, and reproduction in any medium, provided the original author(s) and source are credited**Competing Interests:** The author have declared that no competing interests

Cerebral venous sinus thrombosis (CVST) is presence of a blood clot in the dural venous sinuses. This is a rare, but dangerous condition. CSVT is characterized by a highly variable clinical spectrum, difficult diagnosis, variable etiologies and prognosis. The International Study on Cerebral Vein and Dural Sinus Thrombosis (ISCVT) determined the frequency of the sites of SCVT. The aim of this case study was to show the clinical presentation, the examination we made, the therapy that was ordained and the outcome of the treatment. Case study: A 14-year-old male teenager was admitted to the University Clinic for Neurosurgery in Skopje with GCS 10, accompanied with tonic-clonic epileptic seizures. CT examinations by systems were made, and during the time of recording the patient was given Dormicum 2mg overall dose. CT scan of the brain showed hyperdense zones formation around superior sagittal sinus (SSS), the rest of the medical finding was normal. We ran laboratory tests and the test for hemostasis showed deviation from the normal range. With the ordained therapy the clinical condition of the patient drastically improved. He was discharged home 12 days after the admission. He was given a recommendation for further check-ups by a transfusiologist and regular visits to our clinic. Occlusion of the cerebral veins and dural venous sinuses may occur on the basis of local trauma, neoplasm or infection. Primary aseptic thrombosis may involve either cerebral veins or dural venous sinuses, or both in combination. The clinical picture and the prognosis of intracranial venous thrombosis probably depend largely on the location, extent, and rapidity of development of the venous occlusion. Conclusion: Superior sagittal sinus thrombosis is a condition that can be manifested with diverse and many symptoms and signs, which often can start unexpectedly and can be life-threatening.

Приказ на случај

ТРОМБОЗА НА СУПЕРИОРЕН САГИТАЛЕН СИНУС КАЈ ДЕТЕ

Aleksandra Gavrilovska-Dimovska¹, Андреја Гавриловски², Венко Филипче¹¹ Универзитетска клиника за неврохирургија-Скопје, Универзитет „Св. Кирил и Методиј“, Медицински факултет-Скопје, Република Северна Македонија² Универзитетска клиника за трауматологија, ортопедија, анестезија, реанимација и интензивно лекување - Скопје, Универзитет „Св. Кирил и Методиј“, Медицински факултет, Скопје, Република Северна Македонија

Извадок

Цитирање: Гавриловска-Димовска А, Гавриловски А, Филипче В. Тромбоза на супериорен сагитален синус кај дете- приказ на случај. Арх Ј Здравје 2021;13(1)

doi.org/10.3889/aph.2021.5722

Клучни зборови: венски дурален синус, тромбоза, конзервативен третман***Кореспонденција:** Гавриловска-Димовска Александра, Универзитетска клиника за неврохирургија, Скопје, Република Северна Македонија. E-mail: gavrilovskia@yahoo.com**Примено:** 5-јан-2021; **Ревидирано:** 18-фев-2021; **Прифатено:** 25-фев-2021; **Објавено:** 20-јун-2021**Печатарски права:** ©2021 Александра Гавриловска-Димовска, Андреја Гавриловски, Венко Филипче. Оваа статија е со отворен пристап дистрибуирана под условите на нелокализирана лиценца, која овозможува неограничена употреба, дистрибуција и репродукција на било кој медиум, доколку се цитираат оригиналните автор(и) и изворот.**Конкурентски интереси:** Авторот изјавува дека нема конкурентски интереси.

Тромбоза на церебрален венски синус (CVST) е присуство на тромб во дуралните венски синуси. Ова е ретка, но опасна состојба. CSVT се карактеризира со високо променлив клинички спектар, тешка дијагноза, променлива етиологија и прогноза. Меѓународната студија за церебрална вена и тромбоза на дурален синус (ISCVT) ја утврди фреквенцијата на местата на CVST. Целта на овој приказ на случај беше да ја прикажеме клиничката слика кај наш пациент, испитувањата кои ги одбравме, а не доведоа до конечната дијагноза, терапијата која ја ординиравме и крајниот исход од лекувањето. Приказ на случај: 14-годишен машки тинејџер беше примен на Универзитетската клиника за неврохирургија во Скопје со GCS 10, придружуван од тонично-клонични епилептични напади. Беа направени КТ прегледи по системи и за време на снимањето на пациентот му била дадена Дормикум 2 мг вкупна доза. Од КТ скенот на мозокот се забележани хипердензирани зони околу супериорниот синус сагиталис, а остатокот од КТ скенот бил нормален. Направивме лабораториски тестови, а тестот за хемостаза покажа отстапување од нормалниот опсег. Со ординираната терапија клиничката состојба на пациентот драстично се подобри. Тој беше отпуштен дома 12 дена по приемот. Тој доби препорака за понатамошни прегледи од трансфузиологот и на нашата клиника. Оклузија на церебрални вени и дурални венски синуси може да се појави врз основа на локална траума, неоплазма или инфекција. Примарната асептична тромбоза може да вклучува или церебрални вени или дурални венски синуси, или обете во комбинација. Клиничката слика и прогнозата на интракранијална венска тромбоза веројатно во голема мерка зависи од локацијата, степенот и брзината на развој на венската оклузија. Заклучок: Тромбоза на сагиталниот синус е состојба што може да се манифестира со разновидни симптоми и знаци, кои честопати можат да започнат неочекувано и да бидат опасни по живот.

Introduction

Cerebral venous sinus thrombosis (CVST) is the presence of a blood clot in the dural venous sinuses, which drain blood from the brain. This is a rare, but dangerous condition, affecting predominantly younger people, occurring with an incidence of 3-4 cases/million/year¹ and for children 7 per million². Women tend to be at an increased risk particularly between the ages of 20 - 35, mainly due to the use of oral contraceptive pills and postpartum period¹. Also, one of the biggest factors for cerebral venous thrombosis in childhood is obesity. CSVT is characterized by a highly variable clinical spectrum, difficult diagnosis, variable etiologies and prognosis. It is an interesting data that in poor countries there is an association with the puerperium, with no clear arguments, but probably related to factors such as inappropriate perinatal care, metabolic conditions, and infections associated to childbirth². Clinically nine in ten people with sinus thrombosis have a headache; this tends to worsen over the period of several days. In 40% of acute clinical presentation seizures may be present. These mostly affect only one part of the body and unilateral (occurring on one side), but occasionally the seizures are generalized and rarely can lead to status epilepticus (persistent or recurrent seizure activity for a long period of time). In the elderly, many of the abovementioned symptoms may not occur. Common symptoms in the elderly with this condition are otherwise unexplained changes in the mental status and a depressed level of consciousness. The International Study on Cerebral Vein and Dural Si-

nus Thrombosis (ISCVT) determined the frequency of the sites of SCVT as follows: transverse sinus 86%, superior sagittal sinus 62%, straight sinus 18%, cortical veins 17%, jugular veins 12%, vein of Galen and internal brain veins 11%². In this article we report a case of a 14-year-old patient who developed a superior sagittal sinus thrombosis.

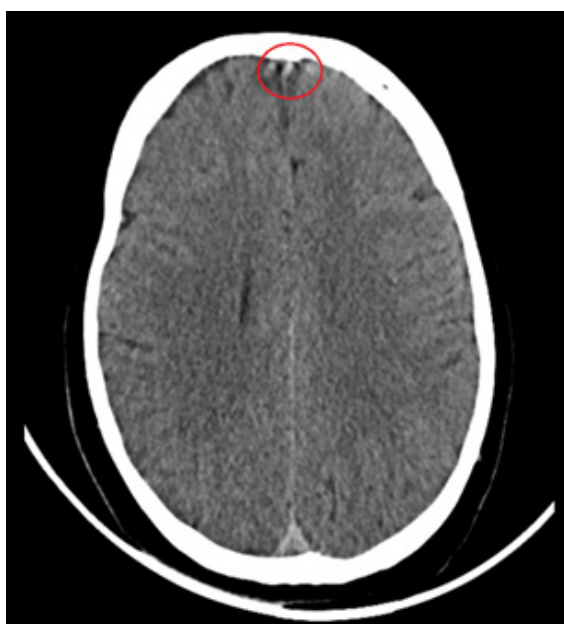
The aim of this case report was to show the clinical presentation, the examination we made, the therapy that was ordained and the outcome of the treatment.

Case presentation

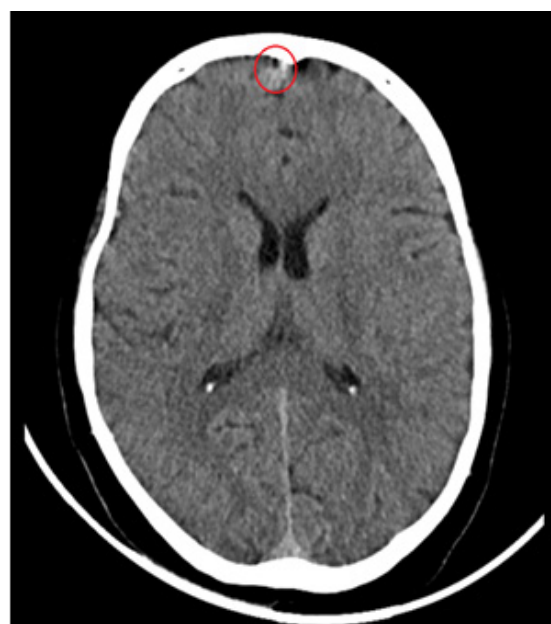
A 14-year-old male teenager, weighing 55kg, was admitted to the University Clinic for Neurosurgery in Skopje. During the check-up the patient was unresponsive, weakly reactive on motoric senses, with eyes open wide, pupils were symmetrically and narrow with movable eyeballs. The condition of consciousness when admitted was GCS 10, accompanied with tonic-clonic epileptic seizures which stopped after giving amp. Diazepam 10 mg i.m. Measured values of TA during admission equaled 160/100 mmHg, oxygen saturation O₂98%. From the anamnestic data received from the patient's family we understood that the patient was found in a lying position on the house yard, without any sign of fall or trauma, uncontactable, with occasionally present epileptic seizures. By further talk with the family we did not get information about any previous diseases, no history for trauma suffered by the patient in the past, no

information for family positive anamnesis. We were also given data that the patient did not consume alcohol or cigarettes, nor he was taking any medicines or drugs. Due to the presence of the frequent epileptic seizures right after the patient check-up, the anesthesiologist was called and CT examinations by systems were made, and during the

time of recording the patient was given Dormicum 2 mg overall dose. The computer findings showed the neck, thorax, abdomen and pelvis in pristine condition. The CT scan of the brain showed hyperdense zones formation around superior sagittal sinus. The rest of the medical finding was normal.



Picture 1. Hyperdense zone frontal b SSS – proximal



Picture 2. Hyperdense zone frontal by SSS - distal

Because of the turbulent clinical condition of the patient, which had started from “full health”, we decided to make a list of examinations to discover the reason for this condition. Right after the admission to our clinic, the presence of medications and narcotics in blood was tested, and the results were negative. Complete laboratory examinations were also made, where except slightly increased values of WBC and increased values of CRP (27.4 mg/L), there were no other deviations from the normal ranges. We ran tests of

hemostasis which showed a deviation from the normal range for the values of activated partial thromboplastin time (23.2 seconds), where the normal range is 27.9-37.7seconds. We detected increased D-dimer values (4311ngr/mL), the normal range being 0-500ngr/mL. The following therapy was given: Tabl. Tegretol 2x200 mg, Sol. Manitol 20% 3x100 ml, amp. Nevaxon 2g, amp. Dexason 2x1, amp. Clexane (Enoxaparin) s.c 2x40 I.E, but Dexason administration was interrupted on the second day of hospitalization. Because there

was not a clear clue for the cause of capturing the consciousness accompanied with epileptic seizures, and the presence of an expansive process in the brain was excluded, MRI of the brain with and without contrast was made, but the finding was normal. In the following days of hospitalization, we continued with the anticoagulant, antibiotic, and antiepileptic and antiedematous therapy (mentioned above) and laboratory examinations were regularly made showing that WBC and CRP values were normalized.

The clinical condition of the patient drastically improved and he was reacting well on the given therapy. On the tests of hemostasis, 4 days after the admission, there were improvements of the activated partial thromboplastin time, which was 26.28 seconds, and of the D-dimer values which were 1035 ngr/mL. After 3 days, a new examination of hemostasis was conducted where activated partial thromboplastin time was in the normal range and the values of the D-dimer were 944.5 ngr/mL. On day 11 after the admission, the tests of hemostasis were again in the limits of normal, and the values of D-dimer decreased to 788.4 ngr/mL. The patient recovered pretty well and he was discharged home 12 days after the admission. He was given a recommendation for further check-ups by a transfusiologist and to make hemostasis controls. Also, he was advised to pay regular check-ups to our Clinic.

Discussion

Occlusion of the cerebral veins and dural venous sinuses may occur on the basis of local trauma, neo-

plasm or infection^{1,2}. Primary aseptic thrombosis may involve either cerebral veins or dural venous sinuses, or both in combination. Several authors have described some of the main angiographic changes in spontaneous thrombosis of the superior sagittal sinus. Arteriovenous shunting is a well-known phenomenon in cerebral infarction due to arterial occlusion. It seems reasonable to attribute the arteriovenous shunting which may occur in the presence of intracranial venous thrombosis to a similar process, namely the frequent pathologic finding of cerebral infarction^{3,4,5}. However, the pronounced, very local arteriovenous shunting into the patent part of the thrombosed cerebral vein (with associated collateral venous drainage) raises the possibility of some other mechanism. The clinical picture and the prognosis of intracranial venous thrombosis probably depend largely on the location, extent, and rapidity of development of the venous occlusion⁶. The classical signs and symptoms of dural venous sinus thrombosis are not difficult to be recognized, but we suspect that cerebral venous thrombosis, particularly when localized and unaccompanied by sinus thrombosis, occurs much more frequently. Intracranial venous thrombosis should be suspected especially in patients with "stroke" of unexplained etiology. As illustrated by our case, papilledema may not be present, particularly during the early stages of the disease^{7,8}.

Conclusion

Superior sagittal sinus thrombosis is a condition that can be manifested with diverse and many symptoms and signs, which often can start un-

expectedly and can be life-threatening. Beside the rarity of this type of thrombosis, even more exceptional was this case of a male teenager. From the list of examinations that we conducted, we succeeded to discover that all of this was regarding to this specific condition, but we did not manage to discover the reasons that prompted this clinical condition. This might have developed to idiopathic thrombosis.

References

1. Wang JW, Li JP, Song YL, Tan K, Wang Y, Li T, et al. Clinical characteristics of cerebral venous sinus thrombosis. *Neurosciences* 2015; 20:292–5. doi: 10.17712/nsj.2015.3.20140625
2. Kashyap AS, Anand KP, Kashyap S. Thrombosis of the cerebral veins and sinuses. *N Engl J Med* 2005; 353:314–5. doi: 10.1056/NEJM200507213530319
3. Wang Xin-Hua, Zhang Lin-Mei, Chai Yi-Ming, Wang Ji, Yu Li-Fei, Zhou Shui-Zhen. Clinical characteristics and outcomes of pediatric cerebral venous sinus thrombosis: An analysis of 30 cases in China. *Front Pediatr* 2019; 7:364 doi: 10.3389/fped.2019.00364.
4. Lebas A, Chabrier S, Fluss J, Gordon K, Kossorotoff M, Nowak-Gottl U, et al. EPNS/SFNP guideline on the anticoagulant treatment of cerebral sinovenous thrombosis in children and neonates. *Eur J Paediatr Neurol* 2012; 16:219–28. doi: 10.1016/j.ejpn.2012.02.005
5. Roach ES, Golomb MR, Adams R, Biller J, Daniels S, Deveber G, et al. Management of stroke in infants and children: a scientific statement from a Special Writing Group of the American Heart Association Stroke Council and the Council on Cardiovascular Disease in the Young. *Stroke* 2008; 39:2644–91. doi: 10.1161/STROKEAHA.108.189696
6. Bousser MG, Ferro JM. Cerebral venous thrombosis: an update. *Lancet Neurol* 2007; 6:162–70. doi: 10.1016/S1474-4422(07)70029-7
7. Qu H, Yang M. Early imaging characteristics of 62 cases of cerebral venous sinus thrombosis. *Exp Ther Med*. 2013; 5:233–6. doi: 10.3892/etm.2012.796
8. Coutinho JM, Ferro JM, Canhao P, Barinagarrementeria F, Bousser MG, Stam J, et al. Unfractionated or low-molecular weight heparin for the treatment of cerebral venous thrombosis. *Stroke* 2010; 41:2575–80. doi: 10.1161/STROKEAHA.110.588822