

## INDICATIONS FOR OPERATION AND RESULTS FROM SURGICAL TREATMENT OF VESICoureTERAL REFLUX

Gani Çeku<sup>1</sup>, Mile Petrovski<sup>2</sup>, Shaban Memeti<sup>2</sup>, Nexhmi Hyseni<sup>1</sup>, Sejdi Statovci<sup>1</sup>, Blerim Berisha<sup>1</sup>

<sup>1</sup> Clinic of Pediatric Surgery, University Clinical Centre of Kosova Prishtina –Kosova

<sup>2</sup> University Clinic for Pediatric Surgery, Faculty of Medicine – Skopje, University Ss. Cyril and Methodius in Skopje, Republic of North Macedonia

### Abstract

**Citation:** Çeku G, Petrovski M, Memeti Sh, Hyseni N, Statovci S, Berisha B. Indications for operation and results from surgical treatment of vesicoureteral reflux. Arch Pub Health 2021; 13 (2) 110-119.

doi.org/10.3889/aph.2021.6009

**Key words:** vesicoureteral reflux, open surgery, uropathy, pediatric urology

**\*Correspondence:** Gani Çeku Clinic of Pediatric Surgery, University Clinical Centre of Kosova Prishtina –Kosova E-mail: ganiceku@hotmail.com

**Received:** 27-Apr-2021; **Revised:** 25-Jul-2021; **Accepted:** 7-Aug-2021; **Published:** 20-Nov-2021

**Copyright:** © 2021, Gani Çeku, Mile Petrovski, Shaban Memeti, Nexhmi Hyseni, Sejdi Statovci, Blerim Berisha. This is an open-access article distributed under the terms of the Creative Commons Attribution License, which permits unrestricted use, distribution, and reproduction in any medium, provided the original author(s) and source are credited.

**Competing Interests:** The author have declared that no competing interests

The main objective of this retrospective study was to evaluate the value of surgical approach in the treatment of children with vesicoureteral reflux (VUR). Material and method: The study was conducted in the period from January 2006 to December 2014, and included children with symptomatic VUR, who were surgically treated. A total of 72 children were treated, of whom 56 were females and 16 were males, aged between 2 and 16 years. They were treated with IV and V grade reflux ureters. Thirty-two of the unilateral refluxes were left-sided, 18 right-sided and 22 both-sided. VUR was diagnosed with Voiding cystourethrography (VCUG). Cohen technique was performed in 64 (90%) patients, Politano-Lead better technique in 4 (5%) patients and Lich-Gregoir technique in 4 (5%) patients. Results: Out of the 72 treated patients, 69 had a postoperative negative finding of VUR on the performed VCUG, indicating a high 95% success rate. In three girls, persistent postoperative reflux was found in postoperative VCUG. In the first patient persistent VUR was unilateral, of V grade. In the second patient, a third-degree VUR was found and the third patient was diagnosed with II grade VUR. Postoperatively, non-febrile UTIs (urinary tract infections) were diagnosed in 23 patients (20 female children and 3 male children) out of 72 patients in total. One female child was hospitalized with febrile UTI and 8 patients or 10% developed febrile UTI within one year of the operative treatment. Conclusion: Open surgery, despite excellent results, is used for more complicated cases, VUR grade IV – V or in previously failed cases, and it does not appear to provide definitive correction of VUR in all patients and does not prevent certain low incidence of UTI postoperatively. Non-febrile UTIs can occur several years after a surgical correction. Endoscopic treatment is an alternative treatment for VUR.

### Клинички истражувања

## ИНДИКАЦИИ И РЕЗУЛТАТИ ОД ХИРУРШКИ ТРЕТМАН НА ВЕЗИКОУРЕТЕРАЛЕН РЕФЛУКС

Гани Чеку<sup>1</sup>, Миле Петровски<sup>2</sup>, Шабан Мемети<sup>2</sup>, Неџми Хисени<sup>1</sup>, Сејди Статовци<sup>1</sup>, Блерим Бериша<sup>1</sup>

<sup>1</sup> Клиника за дејска хирургија, Универзитетски клинички центар на Косово, Приштина – Косово

<sup>2</sup> Универзитетска клиника за дејска хирургија; Универзитет „Св. Кирил и Методиј“ во Скопје, Медицински факултет, Република Северна Македонија

### Извадок

**Цитирање:** Чеку Г, Петровски М, Мемети Ш, Хисени Н, Статовци С, Бериша Б. Оперативни индикации и резултати од хируршки третман на везикоуретерален рефлукс. Арх Ј Здравје 2021;13(2) 110-119.

doi.org/10.3889/aph.2021.6009

**Клучни зборови:** везикоуретерален рефлукс, отворена операција, уропатија, детска урологија

**\*Кореспонденција:** Гани Чеку Клиника за детска хирургија, Универзитетски клинички центар на Косово Приштина – Косово. E-mail: ganiceku@hotmail.com

**Примено:** 27-апр-2021; **Ревидирано:** 25-јул-2021; **Прифатено:** 7-авг-2021; **Објавено:** 20-ное-2021

**Печатарски права:** ©2021 Гани Чеку, Миле Петровски, Шабан Мемети, Неџми Хисени, Сејди Статовци, Блерим Бериша. Оваа статија е со отворен пристап дистрибуирана под условите на нелокализирана лиценца, која овозможува неограничена употреба, дистрибуција и репродукција на било кој медиум, доколку се цитираат оригинално(ите) автор(и) и изворот.

**Конкурентски интереси:** Авторот изјавува дека нема конкурентски интереси.

Главната цел на оваа ретроспективна студија беше да се оцени вредноста на хируршкиот пристап во третманот на деца со везикоуретерален рефлукс (ВУР). Материјали и методи: Студијата беше спроведена во периодот од јануари 2006та до декември 2014та година, и вклучуваше деца со симптоматски ВУР, кои беа хируршки третирани. Вкупно биле третирани 72 деца, од кои 56 биле женски и 16 мажи, на возраст помеѓу 2 и 16 години. Тие беа третирани со IV и V степен рефлуксни уретери. Триесет и два од едностраните рефлукси беа лево, 18 десно и 22 обострани. ВУР беше дијагностициран со Voiding-ова цистоуретрографија на (VCUG). Коенова техника беше применета кај 64 (90%) пациенти, Политано-Лидова техника кај 4 (5%) пациенти и Лих-Грегоарова техника кај 4 (5%) пациенти. Резултати: Од 72 третирани пациенти, 69 имале постоперативен негативен наод на ВУР по извршениот VCUG, што укажува на висока успешност од 95%. Кај три девојчиња е утврден постоперативен рефлукс. Кај првиот пациент перзистирачкиот ВУР беше едностран, од V степен. Кај вториот пациент, беше пронајден ВУР од трет степен, а на третиот пациент му беше дијагностициран ВУР од II степен. Постоперативно, не-фебрилни инфекции на уринарниот тракт (ИУТ) биле дијагностицирани кај 23 пациенти (20 женски деца и 3 машки деца) од вкупно 72 пациенти. Едно женско дете беше хоспитализирано со фебрилна ИУТ и 8 пациенти (10%) развиле фебрилна ИУТ во рок од една година по оперативниот третман. Заклучок: Отворената операција, и покрај одличните резултати, се користи за посложени случаи, ВУР IV - V степен или во претходно неуспешни случаи, и се чини дека не обезбедува конечна корекција на ВУР кај сите пациенти и не спречува одредена ниска инциденца на ИУТ постоперативно. Не-фебрилни ИУТ може да се појават неколку години по хируршката корекција. Ендоскопскиот третман е алтернативен третман за ВУР.

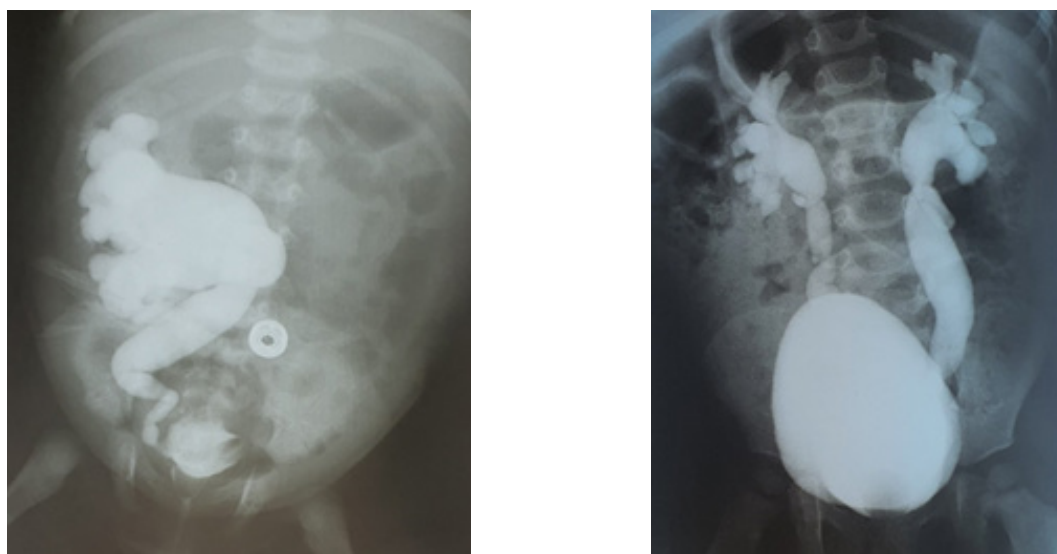
## Introduction

VUR is significant in the siblings of patients with VUR (46%), children with urinary tract infections (UTI) (30%), infants with prenatal diagnosed hydronephrosis (16%) and urogenital abnormalities: posterior urethra valve (PUV) (60%), cloaca (60%), and duplex kidney (46%)<sup>1</sup>. Primary VUR may be due to either abnormal position or integrity of the ureterovesical junction (UVJ) (60%), and duplex kidney (46%)<sup>2,3,4</sup>. The risk for primary VUR varies based on ethnicity, age and gender. Reflux is usually a congenital defect. Spontaneous resolution of primary reflux is common. This is thought to be multi-factorial, in part due to remodeling of the UVJ, elongation of the intravesical ureter, and stabilization of bladder voiding dynamics over time. At birth, the likelihood of spontaneous resolution

is inversely proportional to the initial grade of reflux; approximately 80% of low-grade (I and II) reflux will resolve spontaneously vs. about 50% of grade III reflux. Few or approximately 20% of high-grade (IV and V)<sup>5</sup>.

VUR is defined as active if it occurs during a micturition, while VUR is passive if it is manifested during bladder filling. There are two forms of VUR: primary and secondary.

Primary VUR as the most common form of reflux is due to incompetent or inadequate closure of the ureterovesical junction (UVJ), which contains a segment of the ureter within the bladder wall (intravesical ureter). Normally, reflux is prevented during bladder contraction by fully compressing the intravesical ureter and sealing it off with the surrounding bladder muscles.



**Figure 1.** Unilateral and bilateral VUR (MCUG)

Secondary VUR is a result of abnormally high voiding pressure in the bladder that results in failure of the closure of the UVJ during bladder contraction. Secondary VUR is often associated with anatomic (e.g. posterior urethral valves) or functional bladder obstruction (e.g. bladder bowel dysfunction - BBD) and neurogenic bladder<sup>6</sup>.

In the majority of cases, UTI is diagnosed when evaluating a urinary tract infection. Reflux in children is often hidden behind the symptoms of acute,

chronic or recurrent urinary infection. In some cases, VUR is “accidentally” diagnosed when screening patients at risk (those with a parent, brother or sister with reflux, polycystic kidney or hydronephrosis). Visualization after the first urinary tract infection is indicated in all children younger than 5 years with urinary tract infection, children of any age with febrile urinary tract infection, as well as children with pre-identified hydronephrosis.

A routine renal and bladder ultrasound is obtained in all children after an initial UTI to assess the size and shape of the kidneys, and to detect any renal anatomical abnormality.

Laboratory examination: urine culture, blood counts, serum C-reactive protein, and other hematological tests are routinely determined<sup>7</sup>.

VCUG is the gold standard for diag-

nosing VUR, giving accurate anatomical details and gradation of reflux (Fig. 1). Radionuclide cystography (RNC) is also used to detect reflux. Radioisotope methods: static (DMSA) and dynamic (DTPA) renal scan for visualization of scar changes, renal function assessment and urine transport dynamics<sup>8,9</sup>. Dimercaptosuccinic acid (DMSA) renal scan is superior in detecting renal cortical abnormalities compared to other imaging modalities and should be obtained in patients who are at risk for scarring or appear to have loss of renal parenchyma on renal ultrasound.

A grading system for reflux was established by the International Reflux Study Committee established in 1981 to aid with clinical management and prognostication. Five grades are defined based on the extent of reflux and degree of dilation of the upper tract on imaging<sup>10,11</sup>.

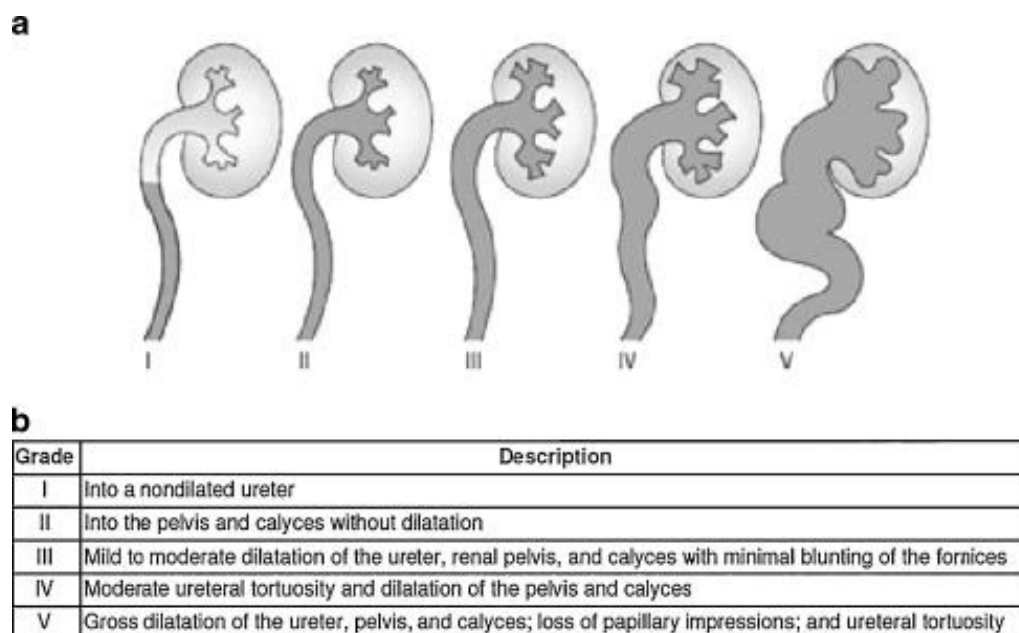


Figure 2. International classification of Vesicoureteral reflux<sup>11</sup>

### Material and Methods

This retrospective study was realized in the period between January 2006 and December 2014, and included

children with symptomatic VUR who were surgically treated at the University Clinical Center, Department of Pediatric Surgery in Prishtina, Kosovo. Grading of the severity of reflux





in all patients was made according to the International Reflux Study committees in 5 groups. The degree of reflux was estimated based on VCUg. Generally accepted indications for surgical treatment were the following: low probability of spontaneous resolution, after unsuccessful endoscopic treatment, high-grade reflux, renal scarring, recurrent pyelonephritis, breakthrough febrile UTI while on continuous antibiotic prophylaxis, parental preference<sup>10</sup>.

A total of 72 children were treated, of whom 56 were females and 16 were males, aged between two and 16 years. The ureters reflux of grade IV and V were treated. VUR was diagnosed with VCUg. The operation was performed under general endotracheal anesthesia.

Open repairs prevent reflux by increasing the length of the intravesical ureter, facilitating compression of the ureter against the detrusor muscle during bladder filling (Table 1). These procedures generally require inpatient hospitalization for management of postoperative pain as well as

temporary urinary catheter drainage. The average time of the intervention was about 80 minutes in unilateral reflux and about 110 minutes in bilateral reflux. During the operation, only 5% of patients received 1 unit of blood or blood derivate. After the open surgical operation, all patients received double antibiotic therapy (ceftriaxone and aminoglycoside). All patients received pain therapy for 2 days. Hematuria was noted in all children in duration from 2 to 3 days. The majority of children had no need of blood transfusion. Urinary catheter was extracted at the 7<sup>th</sup> postoperative day and control ultrasonography was performed. Retrovesical catheter was present only in few of them and it was removed after 2 days. Ureteric stent was placed in only 2 cases. Complete blood count, urine sediment, urea and creatinine level were analyzed every third day.

The postoperative evaluation protocol included renal echo and VCUg after 3 - 6 months. If VCUg and renal ultrasound were normal, prophylaxis with antibiotics was discontinued. Follow-up lasted 4 years on average.

Procedure	Illustration	Advantages	Disadvantages
<b>Extravesical</b> Lich-Gregoir 1961, 1964	 (24)	Bladder is not opened Decreased postoperative hematuria/bladder spasm	Increased risk of urinary retention due to damage to pelvic nerves in bilateral repairs
<b>Intravesical</b> Politano-Leadbetter 1958	 (26)	Creation of longer tunnel	Ureteral kinking/obstruction
Glenn-Anderson 1967	 (27)	Avoids ureteral kinking	Limited tunnel length
Cohen 1975	 (30)	Avoids ureteral kinking Longer tunnel length	Difficult retrograde catheterization

**Table 2.** Open Surgery

The illustrations used in this table are from the references <sup>12,13,17,19</sup>

Hutch in 1952 initially described the technique of elongating the intravesical ureter to create an anti-reflux valve in paraplegic patients with VUR<sup>14</sup>. Since then, multiple additional techniques have been described.

### Extravesical

Lich-Gregoir (1961, 1964): The juxtavesical ureter is dissected and a submucosal groove is created extending laterally from the ureteral hiatus along the course of the ureter. The ureter is placed in the groove and the detrusor is closed over the ureter<sup>15,16,17</sup>.

### Intravesical

Politano-Leadbetter (1958): The ureter is mobilized intravesically and then brought through a new muscular hiatus located superior and lateral to the original mucosal orifice<sup>18,19</sup>.

Cohen (1975): The ureter is advanced through a submucosal tunnel across the trigone to the contralateral bladder wall with the new mucosal orifice located superior to the contralateral orifice<sup>15,20</sup>.

## Results

Out of the 72 surgically treated patients due to VUR, 56 were females and 16 were males (Fig. 2) aged between 2 and 16 years. Thirty-two of the unilateral refluxes were left-sided, 18 right-sided, and 22 two sided. A total of 94 ureters were treated (Table 2, Fig. 4). VUR was diagnosed with VCUG. Sixty-four patients or 90% of cases used the Cohen technique, 5% patients used the Politano-Leadbetter technique and 5% patients the Lich-Gregoir technique (Fig. 5).

Indications for surgical intervention were pronounced grade of UTI (patients with grade IV and V). The postoperative evaluation protocol included renal ultrasound and VCUG after 3 - 6 months. If VCUG and renal ultrasound were normal, prophylaxis with antibiotics was discontinued. Follow-up lasted 4 years on average.

Sixty-nine patients had normal postoperative VCUG, representing a 95% success rate. No patient had significant postoperative hydronephrosis on postoperative renal ultrasound. Persistent postoperative reflux was found in three patients. One was a female child with unilateral VUR grade V, and the other girl had grade III reflux. In the third patient, also a female child, a grade II VUR was found, which we expect to spontaneously recede. This study also included cases of postoperative urinary tract infections (UTIs). Non-febrile UTIs were found in 23 patients (20 female and 3 male children) out of a total of 72 patients. One patient, a female child, was hospitalized due to febrile UTI, and the other 8 patients or 10% had febrile UTI. These UTIs were diagnosed up to one year after surgery.

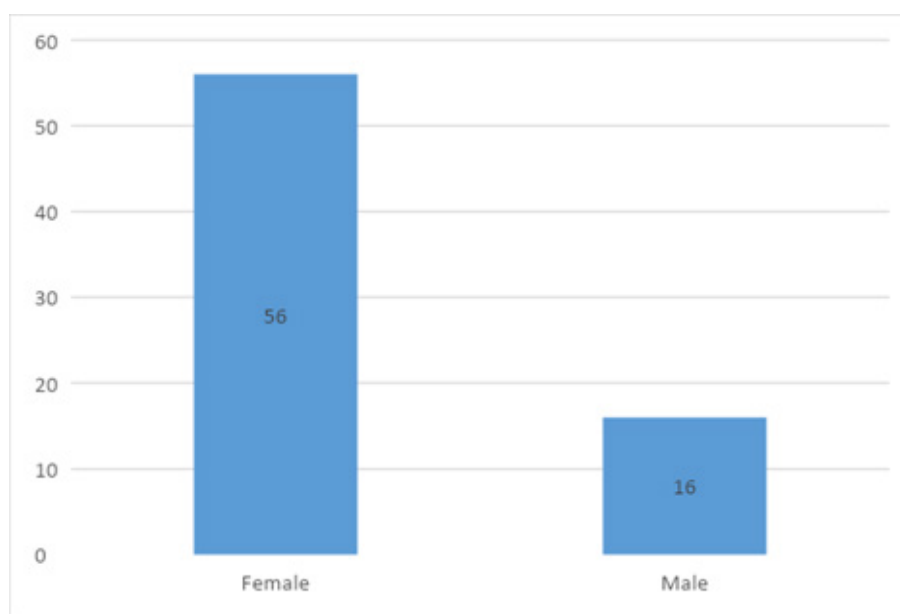
The average time of hospitalization of these patients was 7 days (from 5 to 9 days).

One-sided surgery was used in 50 patients with VUR of the left or right ureter, and bilateral surgery due to VUR was performed in 22 patients.

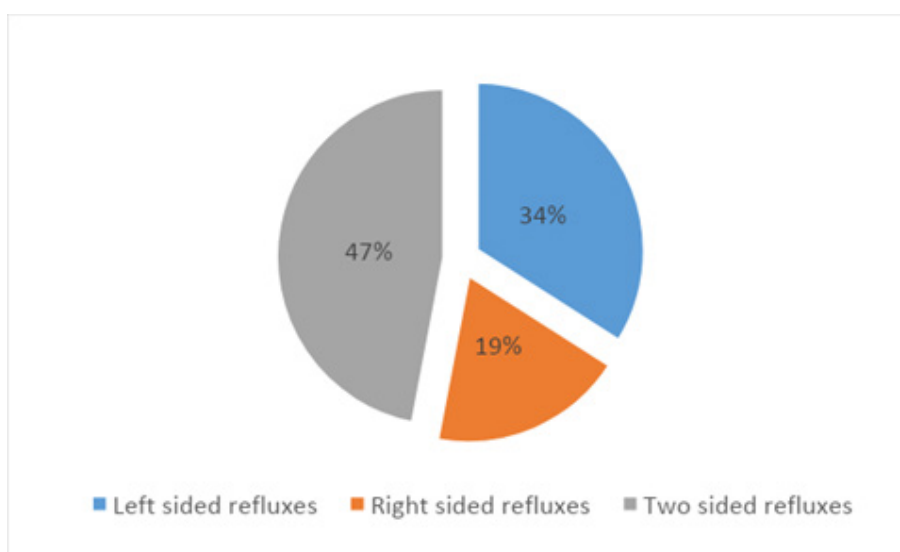
Desired results represented the achievement of proportion for the length of the submucosal tunnel of the ureter to the ureter 4-5:1.

**Table 2.** Characteristics of the study group

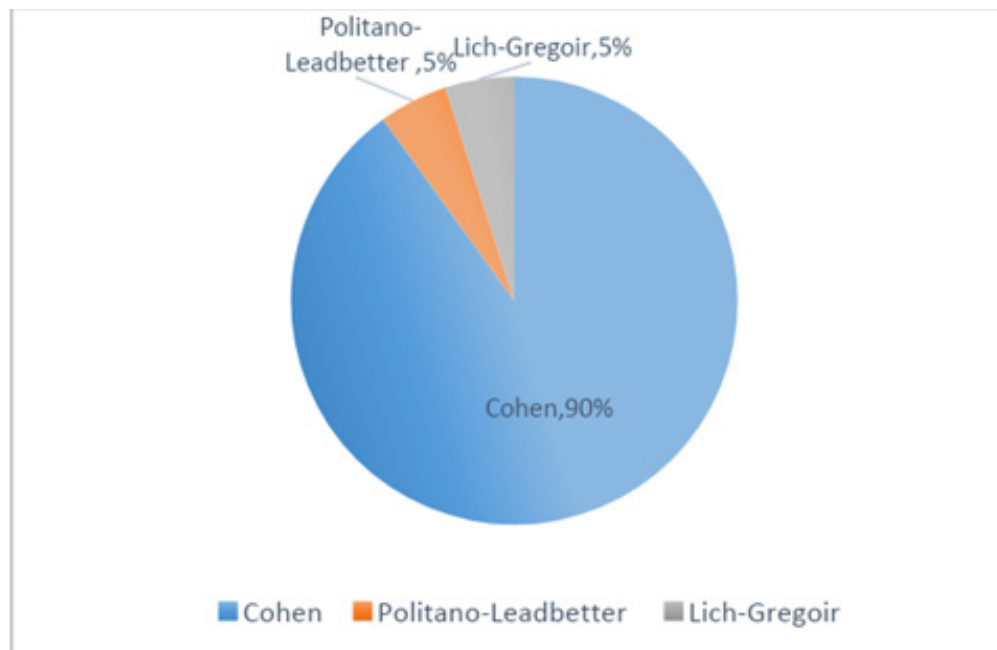
	Male	Female	Male	Female
<b>Number and percentage of patients</b>	16	56	22%	78%
<b>Total number of ureters</b>	94		100%	
<b>Left-sided refluxes</b>	32		34%	
<b>Right-sided refluxes</b>	18		19%	
<b>Two-sided refluxes</b>	22		47%	
<b>Patients treated with Cohen method</b>	64		90%	
<b>Patients treated with Politano-Leadbetter method</b>	4		5%	
<b>Patients treated with Lich-Gregoir method</b>	4		5%	



**Figure 3.** Number of male and female patients with VUR



**Figure 4.** Percentage of the side of ureter affected



**Figure 3.** Percentage of surgical methods used for VUR treatment

## Discussion

VUR is the most common uropathy in children. Treatment of children with reflux tend to prevent kidney infection, kidney damage and complications caused by kidney damage. The treatment includes: pharmacotherapy, surgical treatment and monitoring. Although spontaneous resolution in primary reflux is about 70%, it is common in children younger than 5 years old and in lower grade of reflux (gr I, gr II). It is considered that Grade III reflux has spontaneous resolution of 50%, and the resolution is less likely in children over 5 years. It is unlikely that expressed reflux will spontaneously withdraw. Sterile reflux usually does not lead to reflux nephropathy. Long-term antibiotic prophylaxis in children is considered safe, and surgery used to correct the VUR is highly successful<sup>21,22</sup>. Antibiotic prophylaxis is considered successful if a child does not get urinary infection; does not develop kidney damage, and scarring in parenchyma and the VUR spontaneously resolves<sup>23</sup>.

Anticholinergic and bladder treating can reduce symptoms of dysfunctional voiding and risk of infection.

Depending on sex, age of the patient, grade of reflux, the changes in the renal parenchyma, systemic changes that can note in the presence of VUR will decide which type of treatment would be appropriate choice for the particular patient. Each treatment is indicated in varying degrees of development of the disease<sup>24</sup>.

Open surgery involves modification of dysfunctional ureter – vesical circuit, which creates a ratio of 4:1 to 5:1 in the length for intramural ureter to the diameter of ureter<sup>25</sup>.

Surgical correction of VUR has had excellent results. The success rate has been about 95%. Urinary tract infections have been reported in the postoperative period. The risk of anesthesia as well as the general surgical risks of open surgery should not be neglected<sup>26</sup>.

Open surgery, despite its excellent results, does not seem to promise a definitive correction of VUR by eliminating the possibility of UTIs. Non-fe-

brile UTIs can also occur several years after the surgery.

The International Reflux Study demonstrated the incidence of UTI and febrile UTI in a 10-year study in patients undergoing open surgery. Some of the operated children in this series with pyelonephritis had early surgical complications with ureteral obstruction<sup>27</sup>.

Recurrent reflux was rare, and other factors such as urinary diffusion were the main causes of these recurrences. Most patients were not febrile and were not accompanied by VUR.

Although statistics show that open surgical technique is superior to endoscopic procedure, however endoscopy proved better in terms of time of verticalization of the patients, the need to receive additional drug therapy, blood loss during operation and the duration of the operation<sup>28</sup>. But we cannot favor any surgical method because we believe that both methods have their indicational area in appropriate developmental stage of VUR<sup>21</sup>.

### Conclusions

Open surgical procedure is reserved for more complicated VUR cases (grade IV-V) and for patients with previously failed endoscopic procedure. This surgical method is superior in terms of satisfactory end results. This is relatively inexpensive method, but the time of verticalization of the patients, the need to receive additional drug therapy, long duration of the operation and anesthesia increase the cost.

### Summary points

- Children with VUR are more likely to develop acute pyelonephritis and renal scarring compared to

children without VUR.

- Surgical correction of VUR reduces the occurrence of febrile UTIs.
- The 2010 AUA guidelines recommend consideration of surgical (open or endoscopic) correction of VUR in patients receiving continuous antibiotic prophylaxis with a febrile breakthrough UTI.
- Preoperative reflux grade is the single most important factor affecting the success rate of endoscopic injection.
- Patients with febrile UTI following treatment with endoscopic injection should be evaluated with VCUG to rule out recurrent VUR.

### References

1. Bailey R R. Vesicoureteric reflux in healthy infants and children. In: Reflux nephropathy, p. 59. Edited by Hodson J, Kincaid-Smith P. Masson, New York 1979.
2. Sargent MA. What is the normal prevalence of vesicoureteral reflux? *Pediatr Radiol* 2000; 30:587-593
3. Skoog SJ, Peters CA, Arant BS Jr, Copp HL, Elder JS, Hudson RG et al. Pediatric vesicoureteral reflux guideline panel summary report: clinical practice guidelines for screening siblings of children with vesicoureteral reflux and neonates/infants with prenatal hydronephrosis. *J Urol* 2010; 184 (3):1145-1151
4. Zerlin JM, Ritchey ML, Chang AC. Incidental vesicoureteral reflux in neonates with antenatally detected hydronephrosis and other renal abnormalities. *Radiol* 1993; 187:157-160
5. Elder JS, Peters CA, Arant BS, Ewalt DH, Hawtrey CE, Hurwitz RS et al. Pediatric vesicoureteral reflux



- guidelines panel summary report on the management of primary vesicoureteral reflux in children. *J Urol* 1997;157:1846–1851.
6. Willemsen J, Nijman RJ. Vesicoureteral reflux and videourodynamic studies: results of a prospective study. *Urology* 2000; 55:939.
  7. American Academy of Pediatrics. Practice parameter: the diagnosis, treatment, and evaluation of the initial urinary tract infection in febrile infants and young children. *Pediatrics* 1999;103(4):843 – 52
  8. Jakobsson B, Soderlundh S, Berg U. Diagnostic significance of 99mTc dimercaptosuccinic acid (DMSA) scintigraphy in urinary tract infection. *Arch Dis Child* 1992;67(11):1338 – 42.
  9. The American Urological Association. The management of primary vesicoureteral reflux in children. 1997; 9-15.
  10. Duckett JW, Bellinger MF. A plea for standardized grading of vesicoureteral reflux. *Eur Urol* 1982; 8(2):74-7.
  11. Duckett JW, Bellinger MF. International classification of Vesicoureteral reflux (11) A plea for standardized grading of vesicoureteral reflux. *Eur Urol* 1982; 8(2):74-7.
  12. Glenn JF, Anderson EE. Distal tunnel ureteral reimplantation. *J Urol* 1967;97:623–626.
  13. Retik AB, Colodny AH, Bauer SB. Genitourinary surgery. *Pediatric urology* 1984; 2: 764.
  14. Hutch JA. Vesicoureteral reflux in the paraplegic: cause and correction. *J Urol* 1952; 68:457–469
  15. Lich R Jr R, Lonnie WH, Lawrence A.D. Recurrent urosepsis in children. *J Urol* 1961;86:554–558.
  16. Gregoir W, Regemorter G. Le reflux vesico-ureteral congenital. *Urol Int.* 1964;18:122–136.
  17. Riedmiller H, Gerharz EW. Anti-reflux surgery: Lich-Gregoir extravesical ureteric tunneling. *BJUI* 2008;101:1467–1482.
  18. Politano VA, Leadbetter WF. An operative technique for the correction of vesicoureteral reflux. *J Urol* 1958;79:932–941.
  19. Steffens J, Stark E, Haben B, Trei-eyer A. Politano-Leadbetter ureteric reimplantation. *BJUI* 2006;98:695–712.
  20. Cohen SJ. Uretozystoneostomie: eine neue antireflux Technik. *Aktuelle Urol* 1975;6:1.
  21. Stenberg A, Lackgren G. A new bio-implant for the endoscopic treatment of vesicoureteral reflux: experimental and short term clinical results. *J Urol* 1995; 154(2): 800–3.
  22. Sung J, Skoog S. Surgical management of vesicoureteral reflux in children. *Pediatr Nephrol* 2012; 27(4): 551–61
  23. Baskin L, Kogan B. *Handbook of Pediatric Urology*. Lippincott Williams & Wilkins Philadelphia, 2005
  24. O'Donnell B, Puri P. Endoscopic correction of primary vesicoureteral reflux: results in 94 ureters. *BMJ (Clin Res Ed)* 1986; 293(6559): 1404–6.
  25. Khouri EA, Darius JB. Vesicoureteral reflux. In: Wein AJ, Kavoussi LR, Novick AC, Partin AW, Peters CA, eds. *Campbell-Walsh Urology: Expert Consult Premium Edition*. 10th ed. USA: Elsevier Saunders;2011.3267-310.
  26. Hubert KC, Kokorowski PJ, Huang L, et al. Durability of antireflux effect

- of ureteral reimplantation for primary vesicoureteral reflux: findings on long-term cystography. *Urology* 2012;79(3):675-679.
27. Jodal U, Smellie JM, Lax H, Hoyer PF. Ten-year results of randomized treatment of children with severe vesicoureteral reflux. Final report of the international reflux study in children. *Pediatr Nephrol* 2006;21:785e92
28. Sung J, Skoog S. Surgical management of vesicoureteral reflux in children. *Pediatr Nephrol.* 2012; 27(4): 551-61.