

CASE REPORT

STRAIGHT WIRE AND SEGMENTED
TECHNIQUE IN CANINE RETRACTIONVesna Trpevska¹, Ivan Tanatarec², Daniela Srbinska¹, Aneta Mijoska³¹ University Dental Clinical Center "St. Panteleimon", Department of Orthodontics, Skopje, Republic of North Macedonia² PHO "Dr. Tantarec", Bitola, Republic of North Macedonia,³ Ss Cyril and Methodius in Skopje, Faculty of Dentistry, Department of Prosthodontics, Skopje, Republic of North Macedonia**Abstract****Citation:** Trpevska V, Tanatarec I, Srbinska D, Mijoska A. Straight wire and segmented technique in canine retraction-case reports. Arch Pub Health 2022; 14 (1) 162:171.

doi.org/10.3889/aph.2022.6024

Key words: canine retraction, segmented technique, T-loop, straight-wire technique.***Correspondence:** Vesna Trpevska, University Dental Clinical Center "St.Panteleimon", Department of Orthodontics, Skopje, Republic of North Macedonia. E-mail: vesnarules@hotmail.com**Received:** 23-Nov-2021; **Revised:** 15-Feb-2022; **Accepted:** 25-Feb-2022; **Published:** 23-Jun-2022**Copyright:** © 2022. Vesna Trpevska, Ivan Tanatarec, Daniela Srbinska, Aneta Mijoska. This is an open-access article distributed under the terms of the Creative Commons Attribution License, which permits unrestricted use, distribution, and reproduction in any medium, provided the original author(s) and source are credited.**Competing Interests:** The author have declared that no competing interests

Correct positioning of the canines after their retraction is of great importance for the function, stability and esthetics. Aim: Two case reports were presented to compare the efficiency of two techniques for canine retraction, segmented mechanics using 0.017 x 0.025 TMA T-loop vs sliding straight-wire mechanics using elastomeric chains. Material and methods: The first case describes orthodontic treatment with 0.017 x 0.025 TMA T-loop whereas the second case describes a 9 mm canine retraction using elastomeric chains. Results: Depending on the type of malocclusion both techniques for canine retraction can be used. Post treatment results showed canine retraction with good anchorage control and no mesial movement of the molars. Conclusion: Both techniques provide an optimum rate of tooth movement and none of the methods can be considered superior in terms of tooth movement or side effects, including rotation, tipping, root resorption, anchorage loss, as well as associated pain.

ПРИКАЗ НА СЛУЧАИ

ТЕХНИКА НА ПРАВ ЛАК И СЕГМЕНТИРАНА
ТЕХНИКА ПРИ РЕТРАКЦИЈА НА КАНИНВесна Трпевска¹, Иван Танатарец², Даниела Србиноска¹, Анета Мијоска³¹ Универзитетски клинички центар „Свети Пантелејмон“, Клиника за ортодонција - Скопје, Република Северна Македонија² ПЗУ „Д-р Танатарец“, Бишопа, Република Северна Македонија³ Универзитет Св. Кирил и Методиј во Скопје, Стоматолошки факултет, Клиника за стоматолошка гигиена, Скопје, Република Северна Македонија**Извадок****Цитирање:** Трпевска В, Танатарец И, Србиноска Д, Мијоска А. Техника на прав лак и сегментирана техника при ретракција на канин-приказ на случаи. Арх. Ј. Здравје 2022;14(1) 162:171.

doi.org/10.3889/aph.2021.6024

Клучни зборови: Канин ретракција, сегментирана техника, Т-омча, техника на прав лак***Кореспонденција:** Весна Трпевска, Универзитетски клинички центар „Свети Пантелејмон“, Клиника за ортодонција - Скопје, Република Северна Македонија. E-mail: vesnarules@hotmail.com**Примено:** 23-ное-2021; **Ревидирано:** 15-фев-2022; **Прифатено:** 25-фев-2022; **Објавено:** 23-јун-2022**Печатарски права:** ©2022 Весна Трпевска, Иван Танатарец, Даниела Србиноска, Анета Мијоска. Оваа статија е со отворен пристап дистрибуирана под условите на нелокализирана лиценца, која овозможува неограничена употреба, дистрибуција и репродукција на било кој медиум, доколку се цитираат оригиналните автор(и) и изворот.**Конкурентски интереси:** Авторот изјавува дека нема конкурентски интереси.

Правилна позиција на канините по нивната ретракција е од голема важност за функцијата, стабилноста и естетиката. Цел на трудот: Приказ на два случаи со цел да се спореди ефикасноста на две техники за ретракција на канините, сегментирана техника користејќи 0.017 x 0.025 TMA T-омча версус техника на прав лак користејќи еластомерни ланци. Материјал и метод: Првиот случај е приказ на ортодонтски третман со 0.017 x 0.025 TMA T-омча, додека вториот случај е приказ на 9мм ретракција на канин со еластомерни ланци. Резултати: Во зависност од типот на малоклузија можат да се користат и двете техники за ретракција на канинот. Добиените резултати по ретракција на канинот покажуваат добра контрола на анкората без мезијално движење на моларите. Заклучок: Двете техники покажуваат оптимална стапка на движење на забите и ниеден метод не може да се смета за супериорен во однос на другиот во поглед на движење на забите или несакани ефекти, вклучувајќи ротација, инклинација, ресорпција на коренот, губиток на анкората, како и придружена болка.

Introduction

Anterior dental crowding with the need of canine retraction is the most frequently encountered condition in orthodontic practice¹. Teeth alignment plays an important role in facial esthetics and facial harmony and the presence of maxillary dental crowding is esthetically less acceptable when the 4 maxillary incisors are misaligned². The presence of crowding associated with canine ectopic eruption due to arch length tooth material discrepancy further motivates patients to seek orthodontic treatment^{3,4}. On the other hand there is malocclusion like Angle Class II division I, where the choice of treatment depends on patient's age, etiology of the deep bite, skeletal and dental morphology, vertical dimension, the relationship of the teeth to the surrounding soft tissue structures, length of lip and occlusal plane⁵. Not all patients with deep overbite and increased overjet should be treated with the same mechanics⁶. Canine retraction is a very important step in treatment of patients with crowding, an ectopically erupted canine and first premolar extraction cases. Correct positioning of the canines after retraction is of great importance for the function, stability, and esthetics. Canines can be retracted by friction (sliding) and frictionless (non-sliding) mechanics, using T-loops for tooth movement. Both techniques depend on the type of malocclusion. Continuous mechanics in severely crowded cases results

in round tripping with proclination of the anterior teeth during leveling and aligning. This is followed by en-masse retraction of the entire anterior segment thereby increasing treatment time. On the contrary, the segmental mechanics involves placing brackets only in the posterior segment and initially and individually retracting the canine into the premolar extraction space⁷. This provides space for unraveling the crowding in the upper and lower arch without proclining the anterior teeth. The segmented arch has been designed to deliver relatively light constant forces with reasonable control over the anchor units^{8,9}. The aim of this paper was to present two case reports and to compare the efficiency of the two techniques used.

Case report 1

In this case report, we describe a 16-year-female patient presented with a chief complaint of irregularly placed upper and lower front teeth. The patient was diagnosed as severe Angle's Class II malocclusion with maxillary prognathism and skeletal deep bite. She had dental Class II division 1 malocclusion associated with an increased overjet, 14 mm, and excessive gingival display on smile, 4 mm overbite and super-eruption of maxillary incisors, with occlusal cant, presence of bad oral habits and infantile swallowing. Both arches exhibited minor crowding (Fig.1 and Fig. 2).


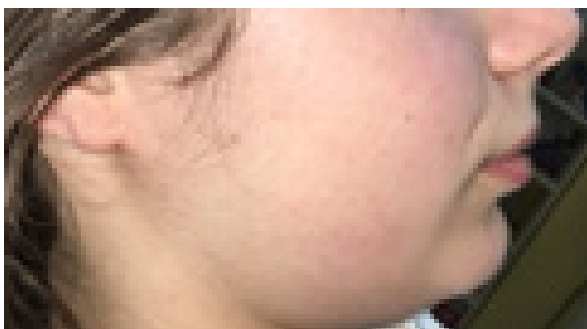


Figure 1. Pretreatment facial photographs.

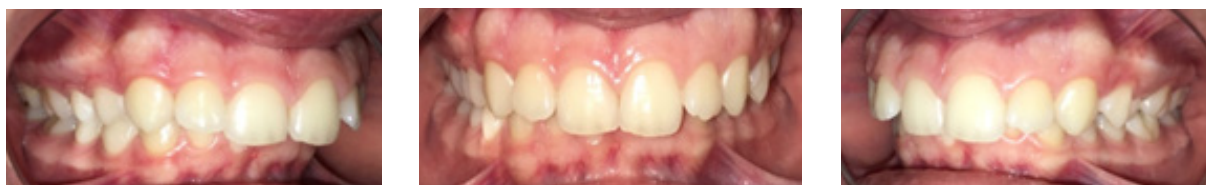

Figure 2. Pretreatment intraoral view of the patient.

Treatment objectives

The primary objective was to correct the deep bite because of its potentially detrimental effects on periodontal health, temporomandibular joint function, as well as esthetics. Due to the patient's vertical maxillary excess, the large interlabial gap and the long lower facial height the treatment objectives were to correct the increased overjet and to reduce the maxillary incisor proclination with retraction of the incisors and canines in the space of the extracted first premolars. Treatment objectives for the occlusion were to correct molar and canine relation and to achieve canine guidance with anterior disclusion. For the soft tissue the treatment objective was to achieve lip competency and ideal facial profile.

Treatment plan and progress

Due to the fact that the patient avoided surgical method for her malocclusion correction, our treatment plan in this case was alternative (camouflage) with upper premolars extraction. The upper first premolars were extracted to reduce the overjet and to align canines properly in the arch form. 0.022 × 0.028 MBT prescription was used. Alignment was done by 0.014 and 0.016 Ni-Ti and active tiebacks. Most of the extraction space was utilized for alignment of canines. In the first phase, we did a 9 mm canine retraction with preserved

vertical dimensions of upper incisors (Fig. 3). Canine retraction incorporated new forces and moments into the system so the good anchorage control to overcome the side effects of the mechanics was crucial. In the second phase of our treatment, we established Class I canine and Class II molar relationship and we achieved ideal overjet and overbite by correcting the incisor inclination along by en-masse retraction of the incisors and their intrusion. Due to the forces and moments created by the system of incisor intrusion and canine retraction, the largest number of posterior teeth was incorporated into posterior segments and a good anchorage control was achieved. For incisor intrusion and canine retraction with elastomeric chains in order to prevent incisor bite deepening we used 0.017 × 0.025 Connecticut intrusion arch and 0.019 × 0.025 stainless steel as base archwire⁷. We ligated and tied the intrusion arch at the lateral incisors and between the central incisors to prevent the loss of distal anchorage and to prevent the extrusive force generated on the incisors when the canine retraction was done¹¹. Molar relation was corrected by light Class II elastics. Finishing was accomplished with coordinated upper and lower 0.019 × 0.025 stainless steel wire (Fig. 4).

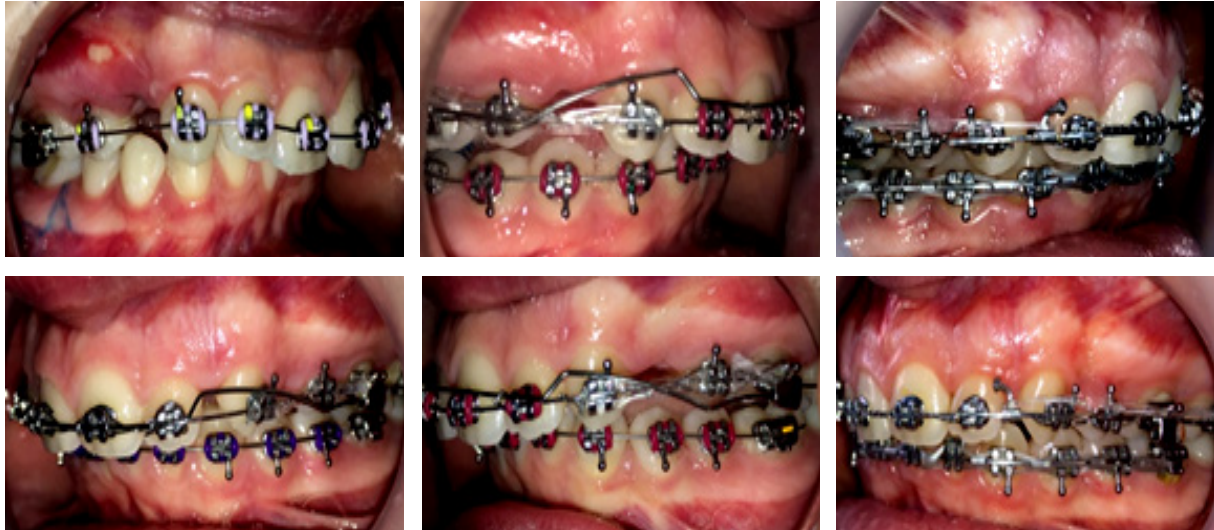


Figure 3. First phase: canine retraction in the extraction space on both sides.

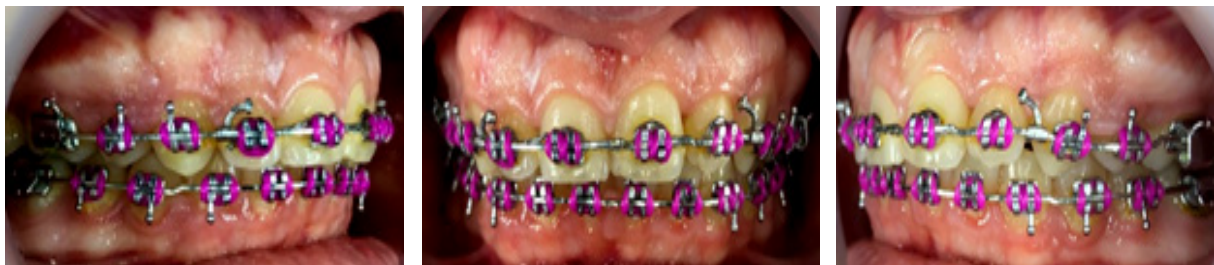

Figure 4. Second phase: incisor intrusion and Class I canine and Class II molar relationship established.

Treatment results

The change in our patient's smile was the most impressive part of the treatment. Outstanding results were achieved with an improved facial profile and smile harmony (Fig 5). With extraction of the first upper premolars, 9 mm retraction of upper canines was achieved.

The Class II molar relation was fixed and Class I canine relationship was corrected and occlusal contacts were obtained between all of the other teeth, especially the canines. A mutually protected occlusion was obtained with stable contacts in centric relation and efficient protrusive movements, as well as right and left lateral movements (Fig. 6).

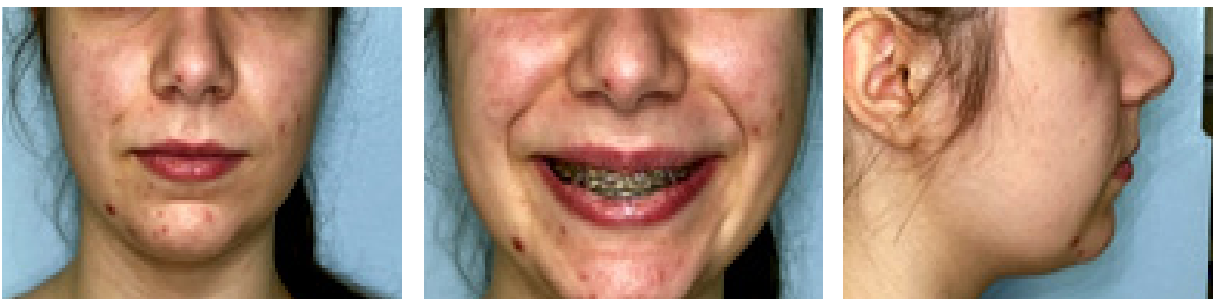


Figure 5. Facial and smile photographs at the end of the treatment

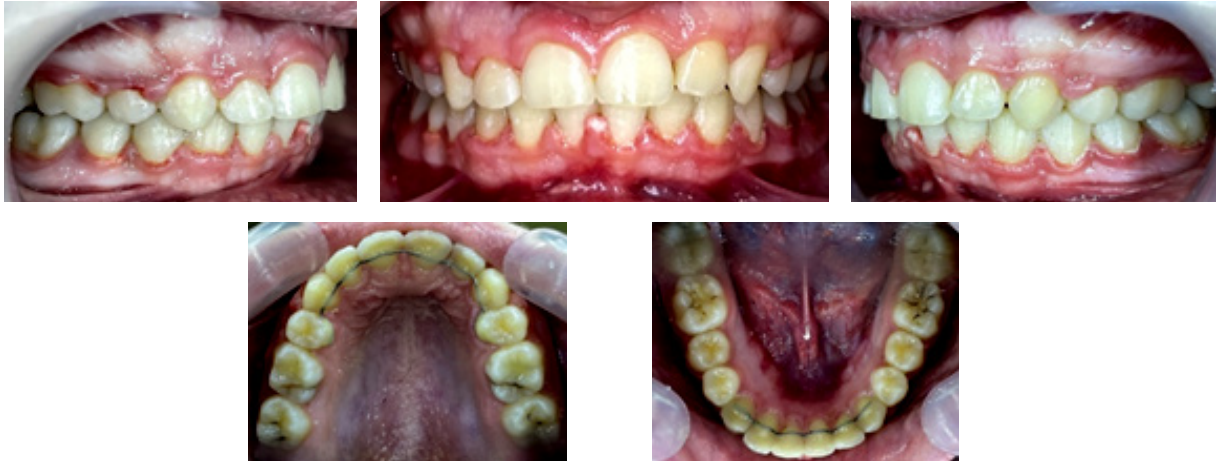

Figure 6. Intraoral view at the end of the treatment.

Case report 2

In the second case report we describe a 17-year-old female patient with chief complaint of her unpleasant

smile, anterior bimaxillary crowding, an ectopically erupted upper left canine, buccally positioned and dental arch asymmetry (Fig. 7).

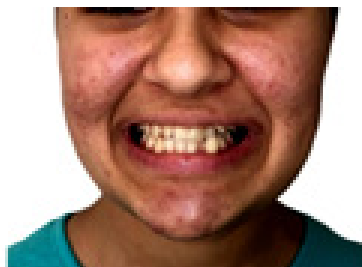


Figure 7. Extraoral view of patient's smile before orthodontic treatment.

Intraoral examination described Angle class I on both sides, III Class tendency on the left side in the canine

region, bimaxillary crowding and palatally placed left lateral incisor (Fig8).

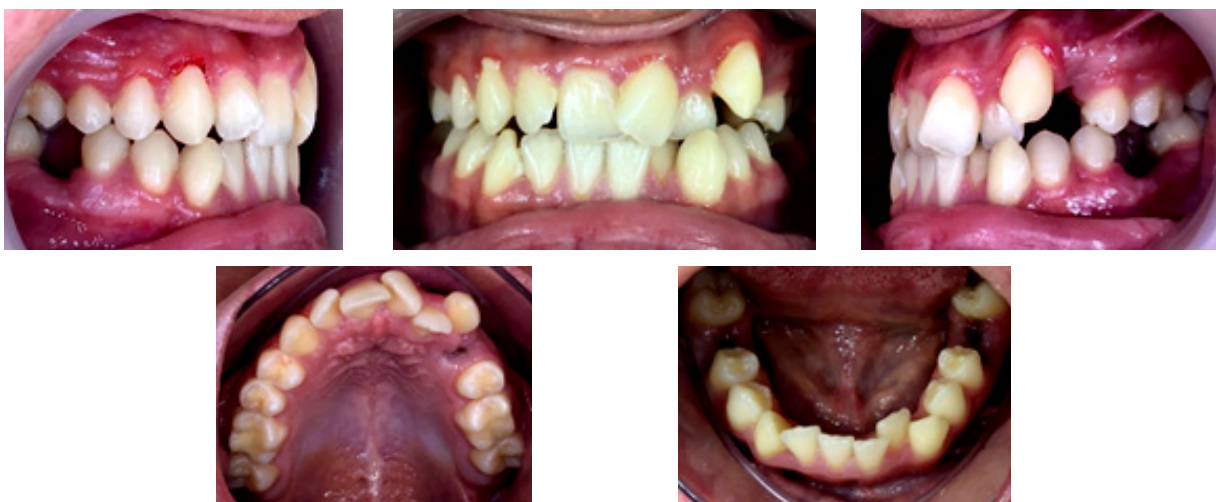

Figure 8. Intraoral view of the patient before treatment.

Orthopantomographic radiograph showed ectopically erupted tooth 23, not erupted teeth 18, 28 and 38 and 48 already in occlusion (Fig.9).

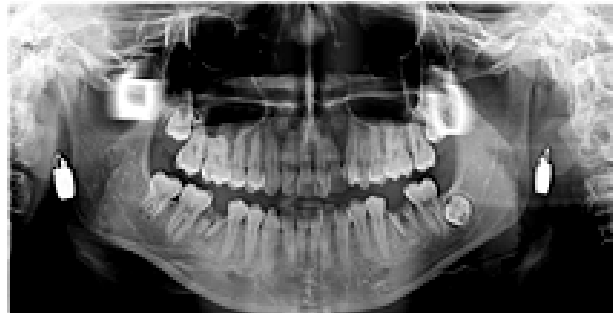

Figure 9. Orthopantomographic radiograph of the patient before treatment.

Treatment plan and progress

Due to space deficiency for canine retraction the upper left first premolar was extracted. Segmented technique involved placing braces only on the teeth of the posterior segment and retracting the ectopically placed canine at the site of the extracted first premolar. This provided space in the arch for leveling the teeth in the anterior segment without their proclination as would have been the case if a straight-wire technique was applied and all teeth were aligned at the same time. An absolute anchorage for canine retraction and no mesial movement of the molars was planned. Properly aligned teeth (upper left lateral incisor and upper right central incisor) were not included in the leveling phase in order to prevent their inclination and to prevent the generation of unfavorable interbracket geometry resulting in the formation of an occlusal cant and thereby in reducing treatment time. With 0.017 x 0.025 segmental titanium molybdenum alloy T-loop, the horizontal force acted on the tooth performing its bodily distalization and its retraction by closing the extraction space. For this case of mesial typing of the canine, the T-loop was activated horizontally until canine correction was achieved. Once the canine cor-

rection was achieved, the activation of the standard T-loop began with a moment of reactivation and horizontal activation, which produced a translatory bodily canine movement. Depending on the position of the canines in the dental arch, anti-rotation bends are used to overcome the tendency for the canines to rotate. The T-loop was positioned closer to the canine so that it occupied an asymmetric position relative to the middle of the distance between the canine and the molar. For a T-loop with a height of 7 mm, a horizontal length of 10 mm with an activation of 3 mm, strength of 100 g was obtained (Fig10). After 5 months of individual canine retraction with 3mm activation at each visit and leveling of teeth with 0.014 nickel titanium arch, an arch protocol was used: 0.016 nickel titanium, 0.016 stainless steel and 0.016 x 0.022 nickel titanium and 0.017 x 0.025 stainless steel. After the treatment with segmented arch and achieving correction of the ectopically positioned canine in Angle class I relationship in 5 months, the second phase of our treatment was continued with straight wire technique in order to correct the maxillary and mandibul crowding, to achieve ideal overjet and overbite and to improve incisor inclination, which, led to improved occlusion and satisfactory

smile for the patient. By presenting this case report, we have highlighted the efficiency of segmented mechanics to optimize the orthodontic treatment, to reduce the duration of treatment time and to achieve ideal results

without side effects on the surrounding teeth and tissues. The use of good biomechanical principles helped us to achieve all treatment goals and objectives in a very short period (Fig11).

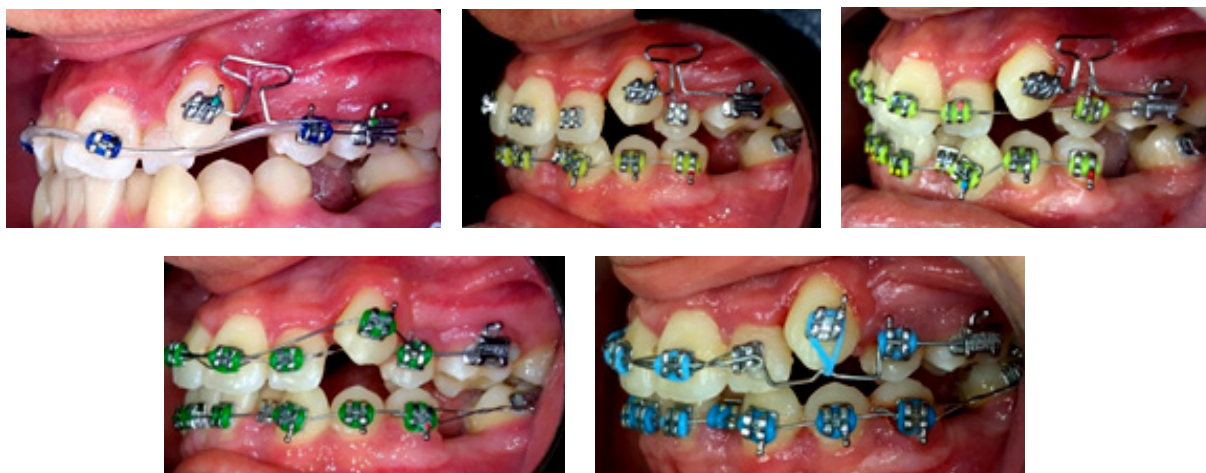

Figure 10. Intraoral view of T-loop and initial phase of orthodontic treatment of canine retraction.

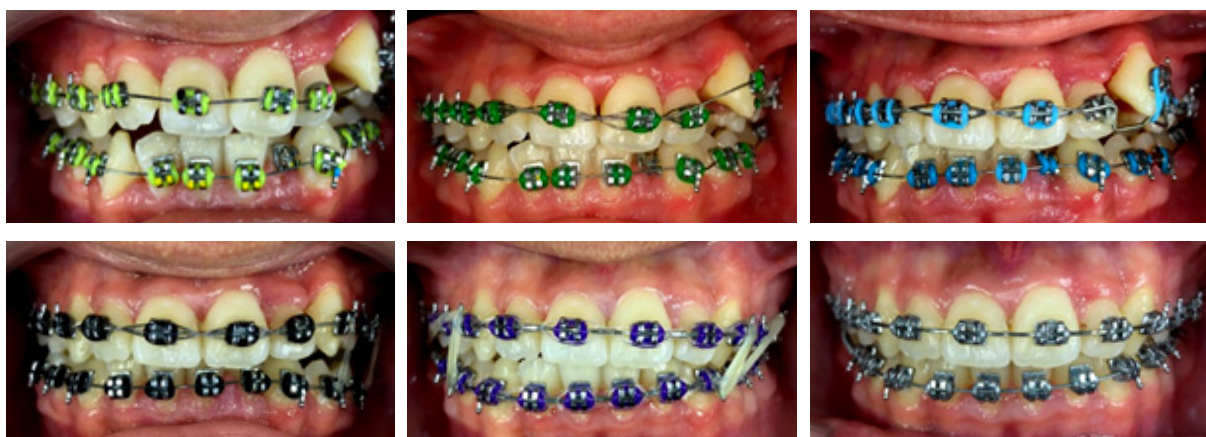


Figure 11. Intraoral view of second phase of orthodontic treatment.

Treatment results

The results of our treatment showed correction of the ectopic placement of the canine. By canine distalization for 7 mm in place of the extracted premolar, the first-class Angle was obtained as well as sufficient space to resolve the anterior maxillary crowding. The inclination of the incisors was improved, the dental midlines coincided with each other and with the face and an ideal over-

jet and overbite were obtained. We achieved improvement of the occlusion and a satisfactory smile for the patient by correcting the maxillary and mandibular crowding and good maintenance of the buccal occlusion on both sides, both in canine and molar regions. We achieved stable occlusal contacts in central occlusion as well as absence of occlusal interferences during mandibular excursions (Fig.12 and Fig.13).




Figure 12. Extraoral view of the patient at the end of the treatment.

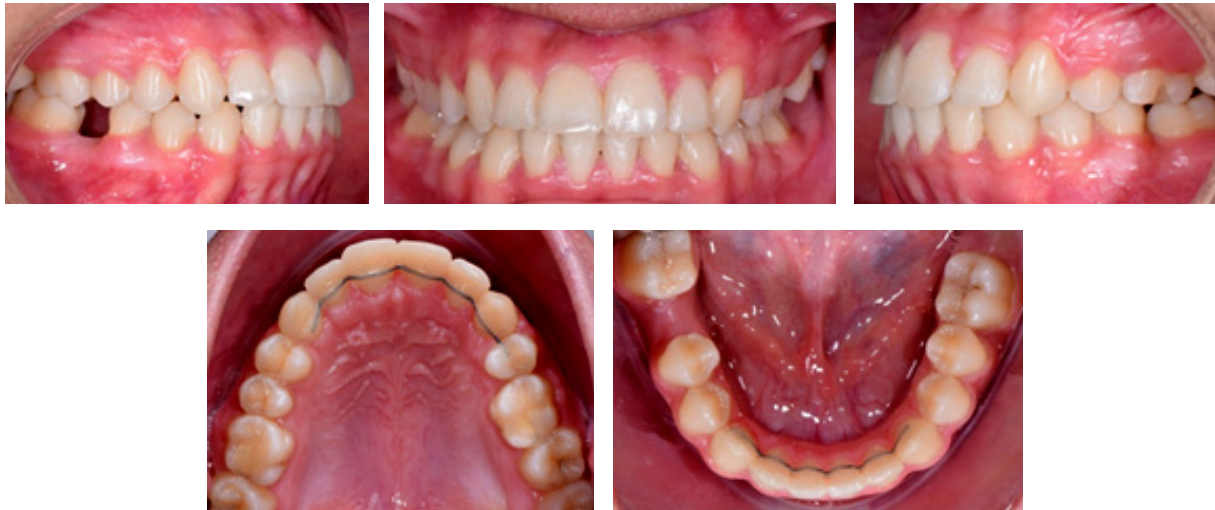

Figure 13. Intraoral view of the patient at the end of the treatment

Discussion

Since the canine retraction procedure takes the longest duration of the entire orthodontic treatment, the main goal is to achieve a rapid and controlled canine retraction with minimal anchorage loss. There are two main canine retraction mechanics: the sectional mechanics which involves frictionless tooth movement, and the continuous mechanics involving friction tooth movement. The friction persists between archwire and bracket when pulling the canine distally using sliding mechanics. On the other hand, frictionless mechanics imply the use of the sectional method such as the use of Burstone's T-loop. Different types of mechanisms have been described for correcting tooth. A controlled tooth movement is always the goal of an orthodontist especially during the phase of canine retraction. De-

pending upon the relationship of the line of action of the force to the center of resistance of the tooth, prediction of tooth movement in the three planes of space is possible¹⁰⁻¹³. Therefore, to preserve supporting tissues and prevent dental trauma and resorption, in addition to performing the treatment in a predictable way and within a shorter period of time, in both cases we decided to extract the first premolars to ensure the proper positioning of the maxillary canines in the dental arch. Segmented TMA T-loop showed three dimensional controls¹⁴. Segmented T-loop served as a retraction spring, which offered not only a distal driving force on the canine but also a moment for anti-distal tipping as well as torque control of canine¹⁵⁻¹⁷. As the retraction progressed, the ectopic tooth was moved distally from the root of the lateral incisor. In the last stage,

a vertical component of force operating on the canine became more desirable. On the other hand, many retraction devices could be used to represent the continuous mechanics technique. However the choice of elastomeric chains used in this study was based on the fact that due to the incisor torque control and the control of upper molars position, the force that they produced was favorable in space closure¹⁸.

Conclusions

Based on the favorable results, it would be safe to assert that the treatment adopted in these clinical cases was the most appropriate one. Because of the large space deficiency for the ectopically placed canine and the facial features, one premolar extraction was critical to treatment success. Controlled movements of the canine with the aid of segmental T-loop and proper anchorage control enabled a simple and predictable approach. Due to the increased overjet and the other symptoms in the second described case, the alternative treatment with upper premolars extraction was crucial for treatment results. Both techniques described provided an optimum rate of tooth movement and none of the methods can be considered superior in terms of tooth movement or side effects, including rotation, tipping, root resorption, anchorage loss, as well as associated pain.

References

1. Bass TB. Observation on the misplaced upper canine tooth. *Den Pract* 1967; 18:25-37.
2. Ma W, Preston B, Asai Y, Guan H, Guan G. Perceptions of dental professionals and laypeople to altered maxillary incisor crowding. *Am J Orthod Dentofacial Orthop* 2014; 146:579-86.
3. Bernabe E, Kresevic V, Cabrejos S. Dental esthetic self-perception in young adults with and without previous orthodontic treatment. *Angle Orthod* 2006; 76:412-6.
4. Chaushu S, Bongart M, Aksoy A, Ben-Bassat Y, Becker A. Buccal ectopia of maxillary canines with no crowding. *Am J Orthod Dentofacial Orthop* 2009; 136:218-23.
5. Dermaut LR, De Pauw G. Biomechanical aspects of Class II mechanics with special emphasis in deep bite correction as part of the treatment goal. In: Nanda R ed. *Biomechanics in clinical Orthodontics 1997 Philadelphia, Pa* W.B. Saunders Co:86-98.
6. Nanda R. The differential diagnosis and treatment of excessive overbite. *Dent Clin North Am*. 1981;25(1):69-84.
7. Burstone CJ. Rationale of the segmented arch. *Am J Orthod* 1962; 48(11):805-822.
8. Burstone CJ, Baldwin JJ, Lawless DJ. The application of continuous forces to orthodontic. *Angle Orthod* 1961:31:1-14.
9. Burstone CJ. The mechanics of segmented arch techniques. *Angle Orthod* 1966:36:99-120.
10. Abraham J. Rate of canine retraction and anchor loss during individual canine retraction. *Biosci Biotechnol Res Commun*. 2020;13(8):445-8.
11. Buyuk SK, Guler MS, Bekci ML. Effect of arch wire size on orthodontic reverse closing loop and

- retraction force in canine tooth distalization: Three-dimensional finite element analysis. *J Orofac Orthop.* 2019;80(1):17-24.
12. Chacko A, Tikku T, Khanna R, Maurya RP, Srivastava K. Comparative assessment of the efficacy of closed helical loop and T-loop for space closure in lingual orthodontics—a finite element study. *Prog Orthod.* 2018;19(1).
 13. Ferreira JB, Silveira GS, Mucha JN. A simple approach to correct ectopic eruption of maxillary canines. *Am J Orthod Dentofacial Orthop.* 2019; 155(6):871-80.
 14. Burstone CJ, Goldberg AJ. Beta titanium: a new orthodontic alloy. *American journal of orthodontics* 1980;77.2:121-132.
 15. Kazuo T, Koenig HA, Burstone CJ. Moment to force ratios and the center of rotation. *Am J Orthod-Dentofacial Orthop* 1988;94.5: 426-431.
 16. Burstone CJ, Koenig HA. Force systems from an ideal arch. *American journal of orthodontics* 1974;65.3:270-289.
 17. Burstone CJ. The biomechanics of tooth movement. *Vistas in orthodontics.* Lea & Febiger Philadelphia 1962;197-213.
 18. Makhoul M, Aboul-Ezz A, Fayed MS, Hafez H. Evaluating the amount of tooth movement and root resorption during canine retraction with friction versus frictionless mechanics using cone beam computed tomography. *Open Access Maced J Med Sci.* 2018; 6(2):384-388.