

CASE REPORT

VENTRICULAR FIBRILLATION AFTER ENDOSCOPIC RETROGRADE CHOLANGIOPANCREATOGRAPHY IN PATIENT WITH LEFT VENTRICULAR ASSIST DEVICE – A CASE REPORT

Antonio Georgiev¹, Hristo Pejkov¹, Oliver Kalpak¹, Marjan Bosev¹, Filip Janusevski¹, Marija Jovanovski Srceva², Nikola Gramatnikovski³

¹ University Clinic of cardiology; Ss. Cyril and Methodius University in Skopje, Faculty of Medicine, Republic of North Macedonia

² University Clinic for Traumatology, Orthopedic, Anesthesia, Reanimation and Intensive Care; Ss. Cyril and Methodius University in Skopje, Faculty of Medicine, Republic of North Macedonia

³ University Clinic for Thoracic and Vascular Surgery; Ss. Cyril and Methodius University in Skopje, Faculty of Medicine, Republic of North Macedonia

Abstract

Citation: Georgiev A, Pejkov H, Kalpak, Bosev M, Janusevski F, Jovanovski Srceva M, Gramatnikovski N. Ventricular fibrillation after endoscopic retrograde cholangiopancreatography in patient with left ventricular assist device – a case report. Arch Pub Health 2022; 14 (1):145-150.

doi.org/10.3889/aph.2022.6047

Key words: LVAD, ventricular fibrillation, ECG, ERCP, blood pressure, pulse, survival

***Correspondence:** Antonio Georgiev, University Clinic of cardiology, Skopje, North Macedonia. E-mail: antoniogeorgiev@yahoo.com

Received: 28-Feb-2022; **Revised:** 27-Mar-2022; **Accepted:** 2-Apr-2022; **Published:** 8-Apr-2022

Copyright: © 2022, Antonio Georgiev, Hristo Pejkov, Oliver Kalpak, Marjan Bosev, Filip Janusevski, Marija Jovanovski Srceva, Nikola Gramatnikovski. This is an open-access article distributed under the terms of the Creative Commons Attribution License, which permits unrestricted use, distribution, and reproduction in any medium, provided the original author(s) and source are credited.

Competing Interests: The author have declared that no competing interests

Congestive heart failure is a growing global health problem. Left ventricular assist device (LVAD) is a method used to extend the life of patients with congestive heart failure as a definitive treatment or to “bypass” the period until heart transplantation. Ventricular arrhythmias in patients with LVAD are not uncommon. The aim of this paper is to present the case of a patient with an already implanted LVAD and the need for appropriate interdisciplinary medical treatment. Case report: We present the case of a 54-year old patient, with implanted LVAD - HeartMate 3 due to severe congestive heart failure. The patient was admitted with jaundice at the PHIU Clinic for Gastroenterohepatology with performed endoscopic retrograde cholangiopancreatography (ERCP) procedure and a stent was placed in the choledochus duct. Immeasurable blood pressure and pulse were recorded in this patient. The ECG was approaching VF (ventricular fibrillation) and it was all asymptomatic by the patient. LVAD mechanical pump leads to continuous blood flow, which means that patients with LVAD not infrequently have no pulse or measurable blood pressure. Also, in patients with LVAD, ECG pulses are with electrical disturbances. VF and ventricular tachycardia (VT) are ventricular arrhythmias that are often seen on ECG in patients with implanted LVAD. Usually these arrhythmias occur with unknown duration and terminate spontaneously. Patients with LVAD are prone to cardiac arrhythmias. The continuous development of medical devices leads to a continuous educational and clinical approach to patients.

ПРИКАЗ НА СЛУЧАЈ

ВЕНТРИКУЛАРНА ФИБРИЛАЦИЈА ПО ЕНДОСКОПСКА РЕТРОГРАДНА ХОЛАНГИОПАНКРЕАТОГРАФИЈА КАЈ ПАЦИЕНТ СО ВГРАДЕН УРЕД ЗА ЛЕВО ВЕНТРИКУЛАРНА АСИСТЕНЦИЈА – ПРИКАЗ НА СЛУЧАЈ

Антонио Георгиев¹, Христо Пејков¹, Оливер Калпак¹, Марјан Бошев¹, Филип Јанушевски¹, Марија Јовановски Срцева², Никола Граматниковски³

¹ Универзитетска клиника за кардиологија; Универзитет „Св. Кирил и Методиј“ во Скопје, Медицински факултет, Република Северна Македонија

² Универзитетска клиника за трауматологија, ортопедија, анестезија, реанимација и интензивна нега, Медицински факултет, Универзитет „Св. Кирил и Методиј“ - Скопје, Р. Северна Македонија

³ Универзитетска клиника за торакална и васкуларна хирургија, Медицински факултет, Универзитет „Св. Кирил и Методиј“ - Скопје, Р. Северна Македонија

Извадок

Цитирање: Георгиев А, Пејков Х, Калпак О, Бошев М, Јанушевски Ф, Јовановски Срцева М, Граматниковски Н. Вентрикуларна фибрилација по ендоскопска ретроградна холангиопанкреатографија кај пациент со вграден уред за лево вентрикуларна асистенција – приказ на случај. Арх Ј Здравје 2022;14(1) 145-150.

doi.org/10.3889/aph.2022.6047

Клучни зборови: LVAD, вентрикуларна фибрилација, ЕКГ, ERCP, крвен притисок, пулс, преживување.

***Кореспонденција:** Антонио Георгиев, Универзитетска клиника за кардиологија, Скопје, Северна Македонија. E-mail: antoniogeorgiev@yahoo.com

Примено: 28-фев-2022; **Ревидирано:** 27-мар-2022; **Прифатено:** 2-апр-2022; **Објавено:** 8-апр-2022

Печатарски права: ©2022 Антонио Георгиев, Христо Пејков, Оливер Калпак, Марјан Бошев, Филип Јанушевски, Марија Јовановски Срцева, Никола Граматниковски. Оваа статија е со отворен пристап дистрибуирана под условите на нелокализирана лиценца, која овозможува неограничена употреба, дистрибуција и репродукција на било кој медиум, доколку се цитираат оригиналниот(ите) автор(и) и изворот.

Конкурентски интереси: Авторот изјавува дека нема конкурентски интереси.

Конгестивната срцева слабост е растечки глобален здравствен проблем. Уредот за лево вентрикуларна асистенција (LVAD) се користи за продолжување на животот на пациентите со конгестивна срцева слабост како дефинитивен третман или за премостување на периодот до трансплантација на срце. Вентрикуларните аритмии кај пациентите со LVAD не се невообичаени. Целта на овој труд е да се прикаже случајот на пациент со веќе вграден LVAD и потребата од соодветен интердисциплинарен медицински третман. Приказ на случај: Ви претставуваме случај на 54-годишен пациент, со вграден LVAD - HeartMate 3 поради тешка конгестивна срцева слабост. Пациентот е примен со иктерус на ЈЗУ Клиниката за гастроентероheпатологија по што е извршена ендоскопска ретроградна холангиопанкреатографија (ERCP) и е поставен стент во холедохусниот канал. Кај овој пациент е регистрирано немерлив крвен притисок и пулс. На ЕКГ е регистрирана VF вентрикуларна фибрилација (VF) и сето тоа беше асимптоматски од страна на пациентот. Механичката пумпа на LVAD води до континуиран проток на крв, што значи дека пациентите со LVAD не ретко немаат пулс или мерлив крвен притисок. Исто така, кај пациентите со LVAD, ЕКГ импулсите се со електрични нарушувања. VF и вентрикуларна тахикардија (VT) се вентрикуларни аритмии кои често се гледаат на ЕКГ кај пациентите со имплантиран LVAD. Најчесто овие аритмии се јавуваат со непознато времетраење и спонтанно завршуваат. Заклучок: Пациентите со ЛВАД се склони кон срцеви аритмии. Континуираноот развој на медицинските помагала води кон континуиран едукативен и клинички пристап во третманот на пациентите.

Introduction

Congestive heart failure (CHF) is a global health problem. Around 26 millions peoples in the world have this growing health problem. Long time congestive heart failure was treated only with medicaments. But with the increase in the incidence of CHF, especially in the elderly population, the need has arisen for the development of devices with mechanical circulatory support such as LVAD^{1,2}.

The first LVAD was set by Dr. DeBakey in the distant 1966. Since then, technological LVADs have been greatly improved. In Europe, about 500 LVADs are implanted annually, while in the USA over 1700 devices. Today LVAD is used to extend the life of these people with CHF. LVAD's are used as a definitive treatment or to bridges the period until cardiac transplantation. The use of LVAD has doubled the survival rate and significantly improved the quality of life of these patients with this health problem^{3,4}.

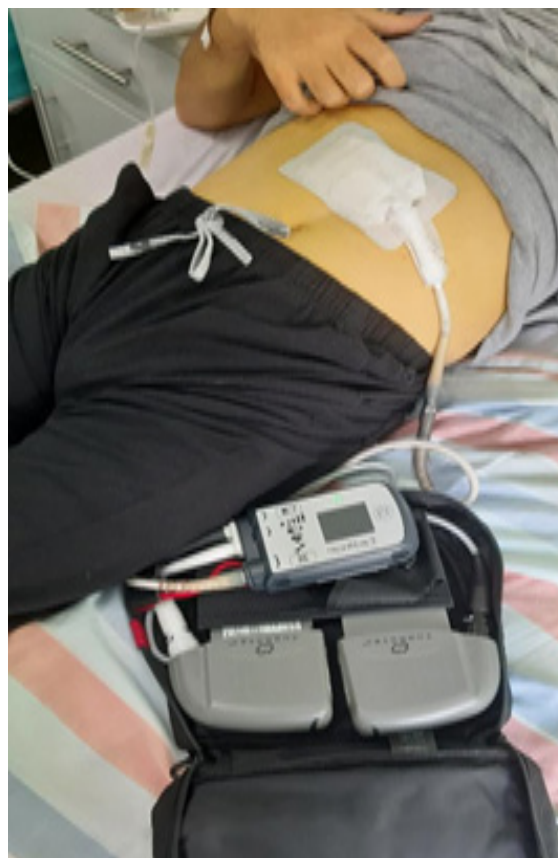Episodes of ventricular arrhythmias are not uncommon in patients with LVAD. Ventricular fibrillation (VF) is a malignant arrhythmia that causes chaotic electrical activity of the heart with a lack of ventricular activity and a sharp drop in cardiac output. It leads to hypoperfusion in all organs of the human body and if you do not react quickly with CPR and DC defibrillation, rapid death occurs. VF is the number one cause of sudden cardiac death in the world⁵.

We report for our experience with a patient with LVAD after performing endoscopic retrograde

cholangiopancreatography(ERCP) who survived a sustained VF of unknown duration and all of this asymptomatic.

Case report

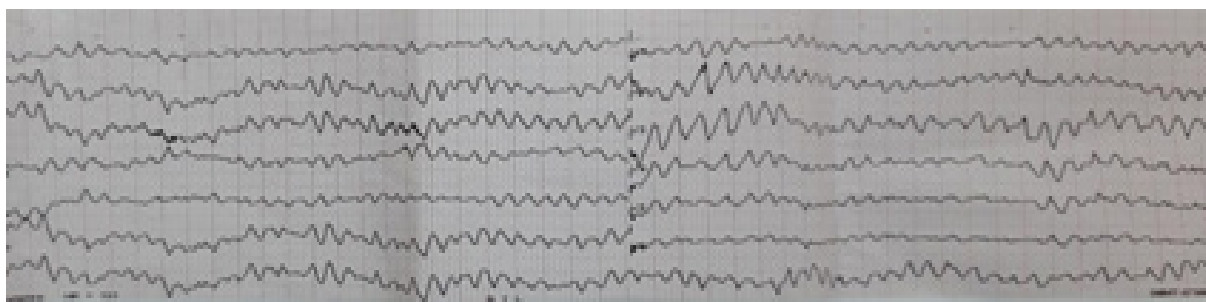
We describe the case of patient A.D., born in 1973, with implanted LVAD - HeartMate3 (picture 1) due to severe congestive heart failure. The patient had a myocardial infarction three years ago when he had a coronary angiography with three stents placed on the coronary arteries. He has a history of hypertensive diseases, he is diabetic and he was also operated on for anulus ventriculisanquans. He smoked cigarettes for 30 years, until three years ago when he quit. The patient was on regular cardiological, diabetic and gastroenterological therapy.



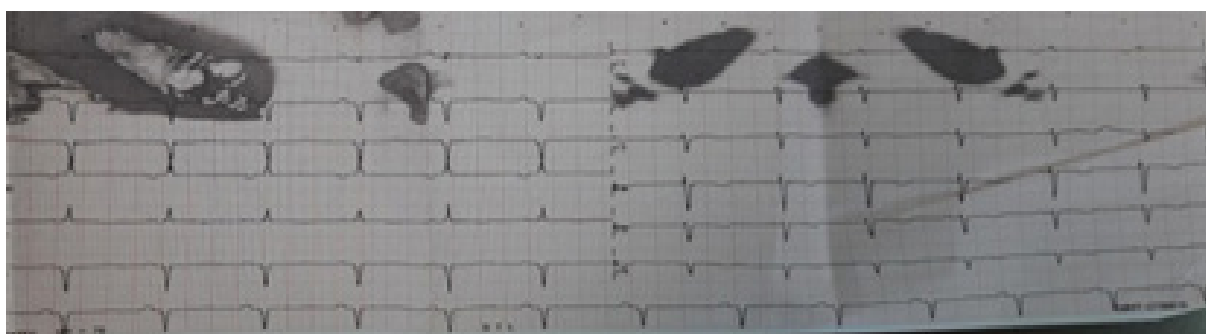
Picture 1. Patient with LVAD

The patient was admitted with jaundice at the PHIU Clinic for Gastroenterohepatology with hyperbilirubinaemia (total bilirubin 88 $\mu\text{mol/L}$ and direct bilirubin 76 $\mu\text{mol/L}$), elevated cholestatic parameters (alkaline phosphatase 88 U/L, GGT 867 U/L). Ultrasound revealed a finding of an inflamed calculous gallbladder and also intra and extrahepatic dilatation of the biliary trunk. It was indicated and performed in the patient ERCP procedure and a stent was placed in the choledochus duct.

The request for an urgent cardiac consultation was due to the patient's immeasurable blood pressure and abnormal ECG. The cardiac examination revealed that the patient had LVAD implanted almost 2 years ago. There was immeasurable blood pressure and pulse, the ECG was approaching sustained VF (picture 2) and it was all asymptomatic by the patient. After twenty minutes, VF spontaneously terminates in a normal stable sinus rhythm (picture 3).



Picture 2. ECG with VF in patient with LVAD



Picture 2. Spontaneous termination of VF in sinus rhythm

Discussion

A medical examination of a patient with immeasurable blood pressure and pulse, with an ECG showing VF and all of it asymptomatic by the patient is a truly dramatic experience. Especially if you have no previous experience with patients with implanted LVAD. Cardiologists usually triage

patients with CHF for cardiac surgery implantation of LVAD. But many cardiologists do not follow these patients after LVAD implantation. The possibility of sudden cardiac death in these patients is a reason for cardiologists and clinicians in general to be cautious in the treatment of these patients and that is why we present this case report.

LVAD enables continuous flow to patients. Indications for LVAD implantation are patients with a low left ventricular ejection fraction (<25%) who were inotropes dependent or were persistently NYHA functional class IIIb or IV despite optimal medical therapy. Also, maximal oxygen consumption under 12 ml/kg/min was often used as an inclusion criterion. Implantation of LVAD is being used to extend the life of patients with congestive heart failure as a definitive treatment or to “bypass” the period until heart transplantation.

HeartMate 3 heart pump is a small, implantable mechanical circulatory device that serves to support patients with heart failure. This pump utilizes technology known as Full Maglev (full magnetically-levitated) Flow technology which reduces the damage to the blood flowing through the pump⁶. The pump is implanted at the apex of the heart where it receives blood from the left ventricle and transmits it through the tube to the aorta. It works by pumping blood in a continuous flow from the left ventricle to the aorta and further to the whole organism. External parts of the LVAD are the controller which is the brain of the whole system and batteries which are the energy of the system. The pump is connected to a cable driveline that runs through the skin of the abdomen and is connected to the controller externally. Parameters that are monitored on HeartMate 3 LVAD are: speed (normal range is 8600 to 9800 rpm), flow (normally 4-6 L/min), power (normal range is 4-7W) and pulsatility index (PI typically range from 3 to 7). It has been medical proven that there is a significant improvement in the ejection fraction after one year of using LVAD^{1,6,7,8}.

The impeller in a mechanical pump rotates thousands of times per minute. This leads to continuous blood flow, which means that patients with LVAD not infrequently have no pulse or measurable blood pressure. Patients with LVADs not infrequently do not have a palpable pulse. Because of that traditional blood pressure measurement by auscultation or automated cuff is less reliable. LVAD guidelines recommend the mean arterial blood pressure to be in the range of 70 to 80 mm Hg. It should not exceed 90 mm Hg. And all this is a usual and expected condition in patients with implanted LVAD⁹.

In patients with LVAD, ECG pulses are with electrical disturbances. These patients have ECG changes that did not precede implantation normally occur. VF and VT are ventricular arrhythmias that are not infrequently seen on ECG in patients with implanted LVAD and strangely they are often well tolerated^{3,5}. But there are also cases in which sudden cardiac death occurs. Most often due to continuous flow and electrical interference these arrhythmias occur with unknown duration and terminate spontaneously. Sacha P. Salzberger et al., describe a case report of a patient who survived a seven-hour sustained VF¹⁰. In our case the patient converted to sinus rhythm after twenty minutes but we have no data when VF started because the patient was not placed on continuous ECG monitoring.

The rapid technological development in the world especially in medical technology leads to constant changes in the treatment of patients. However, VF is a deadly arrhythmia. Patients with LVAD who are exposed to

other medical procedures must be very carefully monitored and specifically monitor their clinical condition. Of course, it should be considered that there is no possibility of electrolyte imbalance that needs to be corrected with fluid and electrolyte. Most patients with LVAD due to CHF already have pre-implanted ICD, in which case the level of defibrillation of the implanted ICD in these patients should be checked and eventually reprogrammed. Also, patients or medical staff should perform a daily self-test on the LVAD to ensure that the device is working properly^{3,9,11,12,15}. The approach to these patients should be multidisciplinary.

Conclusion

We presented this case report to emphasize the specificity as a medical case and awareness of the need for special treatment of these patients. Patients with LVAD should be closely monitored for arrhythmias before / for / after any other more serious medical intervention. The occurrence of VF requires professional supervision and appropriate medical management. The continuous development of medical devices leads to a continuous educational and clinical approach to patients.

References

1. Birati E, Jeddup M. Left ventricular assist devices in the management of heart failure. *Card Fail Rev* 2015;1(1):25–30.
2. Yancy CW, Jessup M, Bozkurt B, et al. 2013 ACCF/AHA guideline for the management of heart failure: executive summary: a report of the American college of cardiology foundation/American heart association task force on practice guidelines. *Circulation* 2013;128:1810–1852.
3. Howard J. E. Left ventricular assist devices (LVADS): history, clinical application and complications. *Korean Circ J* 2019;49(7):568–585.
4. Copeland JG, Arabia FA, Tsau PH, Nolan PE, McClellan D, Smith RG, Slepian MJ. Total artificial hearts: bridge to transplantation *Cardiol Clin* 2003;21(1):101–13.
5. Shashima Nakahara et al. Ventricular arrhythmias after ventricular assist device. *Circulation: arrhythmia and electrophysiology* 2013;6:648–654.
6. Mehra MR, Uriel N, Naka Y, et al. MOMENTUM 3 Investigators. A fully magnetically levitated left ventricular assist device - final report. *N Engl J Med* 2019;380:1618–1627.
7. Slaughter MS, Rogers JG, Milano CA, et al. Advanced heart failure treated with continuous-flow left ventricular assist device. *The New England Journal of Medicine* 2009;361(23):2241–2251.
8. Drakos SG, Mehra MR. Clinical myocardial recovery during long-term mechanical support in advanced heart failure: insights into moving the field forward. *J Heart Lung Transplant* 2016;35:413–420.
9. Potapov E, Antonides C, Crespo-Leiro M, Combes A, Färber G, Hannan M, Kukucka M, Jonge N, Loforte A, Lund L, Mohacsil P, Morshuis M, Netukan I, Ozbaran

- M, Pappalardo F, Scandroglio A, Schweigerr M, Tsui S, Zimpfer D, Gustafsson F* (EACTS chairperson). 2019 EACTS expert consensus on long-term mechanical circulatory support. *European Journal of Cardio-Thoracic Surgery* 2019;56(2):230–270.
10. Salzberg S, Lachat M, Zund G, Turina M. Left ventricular assist device (LVAD) enables survival during 7h of sustained ventricular fibrillation. *European journal of cardio-thoracic surgery* 2004;26:444–446.
 11. Guglin M. Approach to unresponsive patient with LVAD. *The VAD Journal* 4. doi:<https://doi.org/10.13023/VAD.2018.02>.
 12. Mechanical circulatory support: A scientific statement from the American heart association. *Circulation* 2017;123(4).
 13. Poberdy at al. Cardiopulmonary resuscitation in adults and children with mechanical circulatory support. A scientific Statement from the American heart association. *Circulation* 2017;135e1115-e1134.