

CASE REPORT

TORSION OF A LARGE OVARIAN CYST PRESENTED AS AN ACUTE ABDOMEN: CASE REPORT

Sasho Pucakoski¹, Nadezda Spiroska², Andrej Nikolovski³¹ General Hospital Prilep, Republic of North Macedonia² University Surgery Clinic „Ss. Naum Ohridski“; Skopje, Republic of North Macedonia³ University Surgery Clinic „Ss. Naum Ohridski“; Ss Cyril and Methodius University in Skopje, Faculty of Medicine, Skopje, Republic of North Macedonia

Abstract

Citation: Pucakoski S, Spiroska N, Nikolovski A. Torsion of a large ovarian cyst presented as an acute abdomen: Case report. Arch Pub Health 2022; 14 (2).

doi.org/10.3889/aph.2022.6062 Online First

Key words: ovarian cyst; adnexal torsion; acute abdomen;***Correspondence:** Sasho Pucakoski, General Hospital Prilep, Prilep, North Macedonia. E-mail: drpucakoski@gmail.com**Received:** 18-May-2022; **Revised:** 14-Sep-2022; **Accepted:** 17-Sep-2022; **Published:** 23-Sep-2022**Copyright:** © 2022. Sasho Pucakoski, Nadezda Spiroska, Andrej Nikolovski. This is an open-access article distributed under the terms of the Creative Commons Attribution License, which permits unrestricted use, distribution, and reproduction in any medium, provided the original author(s) and source are credited.**Competing Interests:** The author have declared that no competing interests

Patients with acute abdominal pain often end up in the emergency department for surgical treatment. Ovarian cysts can lead to an acute abdomen due to torsion (twisting) or rupture. In this case report we are going to present a 70 y/o female patient with left adnexal torsion, due to a presence of ovarian cyst, presented as an acute abdomen. The patient was enrolled in the emergency department with acute abdomen, nausea and vomiting. After the initial evaluation including a Computerized tomography [CT] scan, the cyst presented as a solid hypodense mass behind the front abdominal wall, with the dimensions of Anteroposterior diameter [APd] 13cm, Laterolateral diameter [LLd] 11cm and Craniocaudal diameter [CCd] 15cm. The possible differential diagnosis [DDx] included cystic tumor [TU] mass on the mesentery as well as a cystic TU on the Urogenital tract (UGT). Intraoperatively adnexal torsion due to an ovarian cyst was found. The cyst and the left adnexa were then removed. Histopathological report showed ovarian hemorrhagic infarction due to a cystic tumor and torsion in the left adnexa.

The diagnosis in such cases is often challenging because often the initial CT report can confuse the surgeon whether the mass arises from the mesentery or the urogenital tract.

ПРИКАЗ НА СЛУЧАЈ

ТОРЗИЈА НА ГОЛЕМА ЦИСТА НА ЈАЈНИК ПРЕЗЕНТИРАНА КАКО АКУТЕН АБДОМЕН: ПРИКАЗ НА СЛУЧАЈ

Сашо Пуцакоски¹, Надежда Спироска², Андреј Николовски³¹ Ојшџа болница Прилеп, Република Северна Македонија² Универзитетска клиника за хируршки болести „Св. Наум Охридски“, Скопје, Република Северна Македонија³ Универзитетска клиника за хируршки болести „Св. Наум Охридски“; Универзитет „Св. Кирил и Методиј“ во Скопје, Медицински факултет, Република Северна Македонија

Извадок

Цитирање: Пуцакоски С, Спироска Н, Николовски А. Торзија на голема циста на јајник презентирани како акутен абдомен: Приказ на случај. Арх Ј Здравје 2022;14(2)

doi.org/10.3889/aph.2022.6062 Online First

Клучни зборови: циста на јајник, торзија на аднекса, акутен абдомен***Кореспонденција:** Сашо Пуцакоски, Општа болница Прилеп, Република Северна Македонија, E-mail: drpucakoski@gmail.com
E-mail: ane_petrusevska@yahoo.com**Примено:** 18-мај-2022; **Ревидирано:** 14-сеп-2022; **Прифатено:** 17-сеп-2022; **Објавено:** 23-сеп-2022**Печатарски права:** ©2022 Сашо Пуцакоски, Надежда Спироска, Андреј Николовски. Оваа статија е со отворен пристап дистрибуирана под условите на нелокализирана лиценца, која овозможува неограничена употреба, дистрибуција и репродукција на било кој медиум, доколку се цитираат оригиналниот(ите) автор(и) и изворот.**Конкурентски интереси:** Авторот изјавува дека нема конкурентски интереси.

Пациентите со акутна абдоминална болка често завршуваат на одделот за ургентни состојби, за хируршки третман. Цистите на јајник може да се манифестираат како акутен абдомен поради настаната торзија или руптура на тие цисти. Во овој приказ на случај прикажуваме 70 годишна пациентка со торзија на лева аднекса, поради присуство на циста на левиот јајник, која се презентираше како акутен абдомен. Пациентката беше примена на одделот за Ургентни состојби со симптоми на акутен абдомен, гадење и повраќање. После иницијалната евалуација која вклучуваше компјутерска томографија [КТ], цистата се презентираше како солидна хиподензна маса зад предниот абдоминален ѕид со димензии на Антеропостериорен дијаметар [АПд] 13 см, Латеролатерален дијаметар [ЛЛд] 11 см и Краниокаудален дијаметар [ККд] 15 см. Диференцијално дијагностички [ДДг] во предвид се земени следните дијагнози: цистична туморска [ТУ] маса која потекнува од мезентериум, како и цистична ТУ маса со потекло од урогенитален тракт [УГТ]. Интраоперативно најдовме торзија на левата аднекса поради присуство на циста на левиот јајник. Цистата заедно со левата аднекса беа отстранети. Хистопатолошкиот извештај покажа хеморагичен инфаркт на јајникот, поради цистичен тумор и торзија на левата аднекса. Постапувањето на точна дијагноза во вакви случаети е честопати предизвикувачка, поради тоа што се случува иницијалниот КТ извештај да го доведе до забуда хирургот за тоа дали масата потекнува од мезентериум, или од урогенитален тракт.

Introduction

According to the National Institute of Health research results, 5% to 10% of women in the United States will require surgical exploration for an ovarian cyst during their lifetime. Of those cysts 13% to 21% will be malignant¹.

However the prevalence in postmenopausal women is 14% to 18%, with an yearly incidence of 8%. It was reported that 30% to 54% of postmenopausal ovarian cysts will persist for years^{2,3}.

Most of the ovarian cysts are asymptomatic, with the cysts being discovered incidentally during ultrasonography or routine pelvic examination in the patients. Some cysts, however, may have a range of symptoms, which sometimes can be severe, such as: discomfort or pain in the lower abdomen due to local organ obstruction, severe pain from rupture or torsion (twisting) of the adnexa⁴.

Case presentation

A 70 years old female patient presented in the emergency department with a severe diffuse abdominal pain which started earlier that day. She was previously diagnosed with atrial fibrillation, treated with oral anticoagulant therapy for 8 years. She underwent Caesarean section 40 years ago.

Physical examination revealed tenderness in the peri umbilical area and the lower abdomen.

Complete blood analysis presented with abnormal findings as of: Leukocytes 21 ($3.5 - 10.0 \times 10^9/L$), with Neutrophils 8.4 ($2.0 - 8.0 \times 10^9/L$), Lymphocytes 0.06 ($1.2 - 3.2 \times 10^9/L$), C-reactive protein [CRP] 115.5 (0.0 - 5.0 mg/L), Serum Iron [Fe] 2.0 (6.6 - 28.3 $\mu\text{mol/L}$). Computerized tomography, according to the radiography report (Native series) showed larger hypodense cystic TU formation, in some places with a thickened wall in the periumbilical area with possible connection to the mesentery and/or left adnexa. The TU suppressed the intestines. Its dimensions were as follows: APd 13 cm, Lld 11 cm, CCd 15 cm (Figure 1,2,3).

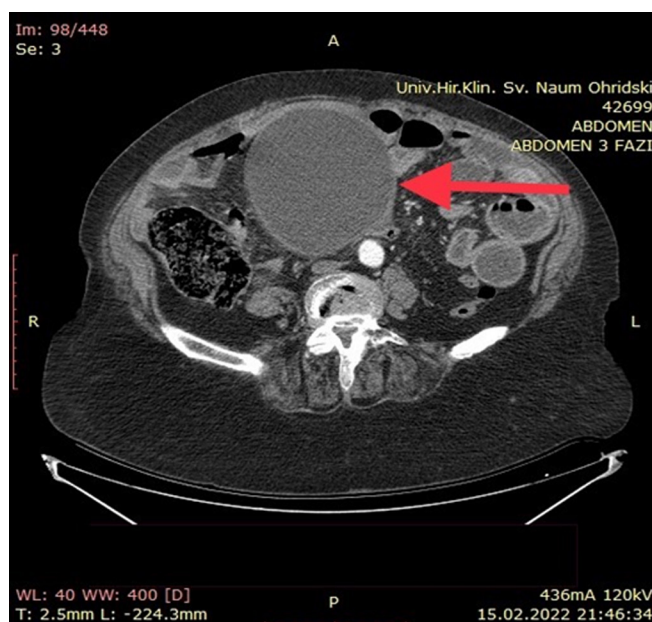


Figure 1 . Axial CT scan of the abdomen showing the cystic tumor (arrow)

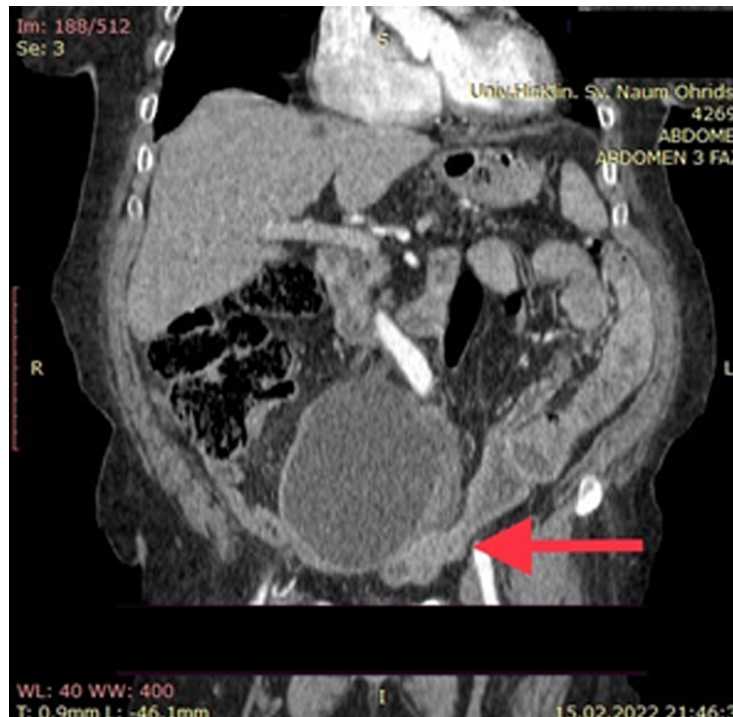


Figure 2. Possibly connected to the left adnexa and/or mesentery (arrow)

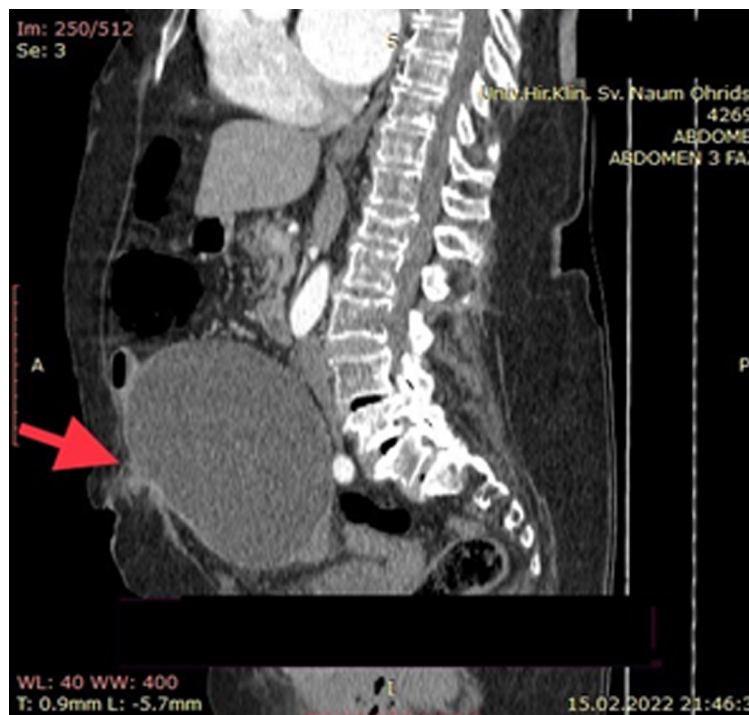
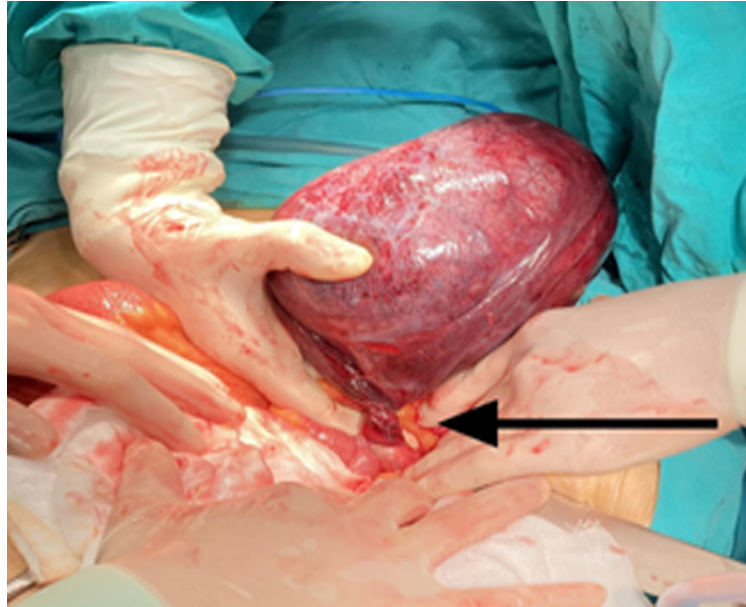


Figure 3. CT Sagittal presentation of the mass (arrow)

Indication for emergency laparotomy was set.

Intraoperatively a huge central abdominal cyst arising from the left adnexa was found with a moment

of torsion (twisting) in the left adnexa. The mass was then removed together with the left adnexa. Ovarian artery and tubal ligature were made (Picture 1).



Picture 1 . Twisted left ovarian cyst

In the postoperative period the intestinal function was reestablished. The patient was discharged on day 6 post operation. Seroma of the surgical wound occurred at first check up. It was treated in an outpatient set-up. The pathology report described a cystically changed ovarium with massive oedema, congestion, extensive hemorrhage, and polymorphonuclear infiltration. Ovarian infarction, due to torsion (twisting) of the cyst occurred.

There was no presence of atypical or malignant cells reported in the Report.

Discussion

Large intra abdominal cystic lesions can present with certain diagnostic challenges and difficulty in the setting of straight diagnosis due to the image overlapping of different abdominal entities. In some cases the cystic lesion can be recognized to arise from a certain organ in the abdominal cavity. Therefore the diagnosis is more straightforward. Oc-

asionally the presentation of these large cysts can mislead and cause diagnostic difficulties⁵.

Large abdominal masses can compress local organs, such as intestines and lead to obstruction and potential necrosis of these organs⁶. Therefore the need for urgent surgery in such masses sometimes is necessary in order to avoid irremediable changes of the intestines.

Female patients admitted to emergency department with symptoms of an acute abdomen, nausea and vomiting, should always be examined for intestinal pathologies as well⁶. In our case, the intestines and other surrounding organs were non-compromised.

Detorsion of a twisted ovarian cyst is preferable management in younger patients, in order to salvage ovarian function and preserve its fertility⁷.

Most of the cysts are benign, but there are a few that are malignant and they're presenting with a very low rate of survival. In such cases

the diagnosis should be obtained surgically, while the biopsy and aspiration can often be harmful⁸. Age factor is important in terms of increased malignancy rate possibility. Median age for ovarian carcinoma was found to be 63 years⁹. Sharma et al. included 186 postmenopausal women who underwent a surgical evaluation for ovarian cyst 10 cm or larger. Malignant process was found in 13%, which indicates that the larger the cyst gets, the bigger the chance for it being malignant is¹⁰. Knowing these facts, the clinicians should try to balance the risk of surgery for what may be a benign mass and the risk of a delay of diagnosis in potential malignancy⁸.

Conclusion

A giant ovarian cyst is a rare condition and management is challenging, mainly because of the difficulty to set the correct diagnosis upfront.

Occasionally it can present as acute abdomen due to a cystic torsion (twisting). No matter the diagnostic challenges, surgery is the mainstay of its treatment in order to avoid compromise and gradual worsening of the patient's condition. Even more when the patient presents with an acute abdomen, surgery is indicated no matter the origin of the cyst lesion.

References

1. NIH consensus conference. Ovarian cancer. Screening, treatment, and follow-up. NIH Consensus Development Panel on Ovarian Cancer. *JAMA*. 1995;273(6):491-7. PMID: 7837369.
2. Modesitt SC, Pavlik EJ, Uealnd FJ, DePriest PD, Kryscio RJ, Van Nagell JR. Risk of malignancy in unilocular ovarian cystic tumor less than 10centimeters in diameter. *Obstet gynecol* 2003; 102:594-599
3. Greenlee RT, Kessel B, Williams CR, Riley TL, Ragard LR, Hartge P, et al. Prevalence, incidence, and natural history of simple ovarian cysts among women >55 years old in a large cancer screening trial. *Am J Obstet Gynecol* 2010; 202(4):373.e1-9.
4. Bottomley C, Bourne T. Diagnosis and management of ovarian cyst accidents. *Best Pract Res Clin Obstet Gynaecol*. 2009; 23(5):711-724.
5. Yacoub JH, Clark JA, Paal EE, Manning MA. Approach to cystic lesions in the abdomen and pelvis, with radiologic-pathologic correlation. *Radiographics* 2021;41(5):1368-1386.
6. Duran A, Duran FY, Cengiz F, Duran O. Intestinal Necrosis due to Giant Ovarian Cyst: A Case Report. *Case Rep Surg*. 2013;2013:831087.
7. Dasgupta R, Renaud E, Goldin AB, Baird R, Cameron DB, Arnold MA, et al. Ovarian torsion in pediatric and adolescent patients: A systematic review. *J Pediatr Surg* 2018;53(7):1387-1391.
8. Ross EK, Kebria M. Incidental ovarian cysts: When to reassure, when to reassess, when to refer. *Cleve Clin J Med* 2013;80(8):503-514.
9. Sharma A, Gentry-Maharaj A, Burnell M, et al; UK Collabora-

tive Trial of Ovarian Cancer Screening (UKCTOCS). Assessing the malignant potential of ovarian inclusion cysts in postmenopausal women within the UK Collaborative Trial of Ovarian Cancer Screening (UKCTOCS); A prospective cohort study; BJOG 2012; 119:207-219

10. Ghezzi F, Cromi A, Bergamini V, Uccella S, Siesto G, Franchi M, Bolis P. Should adnexal mass size influence surgical approach? A series of 186 laparoscopically managed large adnexal masses. BJOG. 2008;115(8):1020-1027.

SK. The dichotomy of relative humidity on indoor air quality. Environ Int 2007;33:850-857.