

ORAL HEALTH

NON-SYNDROMIC MULTIPLE TEETH IMPACTION - CASE REPORT

Daniela Srbinska¹, Vesna Trpevska¹, Aneta Mijoska²¹ University Dental Clinical Centre "St. Panteleimon", Skopje, Republic of North Macedonia² Faculty of Dentistry, Ss. Cyril and Methodius University in Skopje, Republic of North Macedonia

Abstract

Citation: Srbinska D, Trpevska V, Mijoska A. Non-syndromic multiple teeth impaction - case report. Arch Pub Health 2023; 15 (1). 134:144. doi.org/10.3889/aph.2023.6095

Key words: tooth eruption, impacted teeth, first permanent molar, second permanent molars, Schwartz removable appliance.

***Correspondence:** Daniela Srbinska, Department of Orthodontics, University Dental Clinical Centre "St. Panteleimon", Skopje, North Macedonia, E-mail danielasrbinska7@gmail.com

Received: 1-Feb-2023; **Revised:** 1-Jun-2023;

Accepted: 10-Jun-2023; **Published:** 30-Jun-2023

Copyright: © 2023, Daniela Srbinska, Vesna Trpevska, Aneta Mijoska. This is an open-access article distributed under the terms of the Creative Commons Attribution License, which permits unrestricted use, distribution, and reproduction in any medium, provided the original author(s) and source are credited.

Competing Interests: The author have declared that no competing interests

Tooth eruption is a continuous process by which developing teeth move through the soft tissue, oral epithelium, jaw bones and overlying mucosa, to emerge in the oral cavity, contact the teeth of the opposing dental arch, and enable teeth functional position in mastication. Abnormal tissue interactions during tooth development may be potentially revealed as ectopic tooth development, ectopic eruption or tooth impaction. In human dentition, permanent tooth impaction is relatively common. Impaction of the first permanent molar is an uncommon condition and few cases are reported in the literature. It is essential to diagnose and treat the impacted permanent molars as early as possible because treatment at a later stage is usually more complicated due to the tendency of malocclusion to increase with time. We report a case with impaction of the maxillary first permanent molar and impaction of all, maxillary and mandibular permanent second molars. This condition compromise masticatory function. Unilateral mastication also compromises the function of temporomandibular joint. The aim of this case-report was to present orthodontic treatment with Schwartz removable appliance in a patient with maxillary left-side impaction of the second premolar, first molar and second molar. The goal of the first phase was positioning the maxillary first molar into the dental arch with good bone and periodontal support. The surgical intervention, operculectomy, was done and the orthodontic treatment started by traction of the first molar with elastic ligature attached from the bonded bracket to the mobile appliance. One month later the tooth movement was obvious.

ОРАЛНО ЗДРАВЈЕ

ИМПАКЦИЈА НА ПОВЕЌЕ ЗАБИ БЕЗ ПРИСУСТВО НА СИНДРОМ - ПРИКАЗ НА СЛУЧАЈ

Даниела Србиноска¹, Весна Трпевска¹, Анета Мијоска²¹ Универзитетски стоматолошки клинички центар „Св. Пантелејмон“, Скопје, Република Северна Македонија² Стоматолошки факултет, Универзитет „Св. Кирил и Методиј“ во Скопје, Република Северна Македонија

Извадок

Цитирање: Србиноска Д, Трпевска В, Мијоска А. Импакција на повеќе заби без присуство на синдром - приказ на случај. Арх Ј Здравје 2023;15(1) 134:144. doi.org/10.3889/aph.2023.6095

Клучни зборови: ерупција на заб, импактирани заби, прв траен молар, втори трајни молари, подвижен апарат според Шварц.

***Кореспонденција:** Даниела Србиноска, Оддел за ортодонија, Универзитетски стоматолошки клинички центар „Св. Пантелејмон“, Скопје, Р. Северна Македонија, Е-маил: danielasrbinska7@gmail.com

Примено: 1-фев-2023; **Ревидирано:** 1-јун-2023; **Прифатено:** 10-јун-2023; **Објавено:** 30-јун-2023

Печатарски права: ©2023 Даниела Србиноска, Весна Трпевска, Анета Мијоска. Оваа статија е со отворен пристап дистрибуирана под условите на нелокализирана лиценца, која овозможува неограничена употреба, дистрибуција и репродукција на било кој медиум, доколку се цитираат оригиналниот(ите) автор(и) и изворот.

Конкурентски интереси: Авторот изјавува дека нема конкурентски интереси.

Ерупцијата на забите е континуиран процес со кој забите во развој се движат низ мекото ткиво, оралниот епител, коските на вилиците и слезницата што ги покрива, за да излезат во усната шуплина, да дојдат во контакт со забите од спротивниот забен лак и да ја овозможат функционалната положба на забите при џвакање. Абнормалните ткивни интеракции за време на развојот на забите потенцијално може да се откријат како ектопичен развој на забите, ектопична ерупција или импакција на забите. Кај човекото забало, импакција на траен заб е релативно честа појава. Импакција на првиот траен молар е невообичаена појава и само неколку случаи се пријавени во литературата. Импактирани трајни катници неопходно е да се дијагностицираат во рана фаза и да се третираат што е можно порано, бидејќи третманот во подоцнежната фаза е обично покомплициран поради тенденцијата да се зголеми можноста за развој на денална малоклузија со текот на времето. Во овој приказ на случај станува збор за импакција на првиот максиларен траен молар и импакција на сите, максиларните и мандибуларните трајни втори молари. Оваа состојба ја оневозможува џвакалната функција на пациентот. Едностраната мастикација исто така влијае негативно и на темпоромандибуларниот зглоб. Целта на овој приказ на случај беше да се претстави ортодонски третман со мобилен апарат според Шварц кај пациент со еднастрана максиларна импакција на лев втор премолар, првиот молар и вториот молар. Целта на првата фаза беше позиционирање на максиларниот прв молар во забниот лак со добра коскена и пародонтална поддршка. Беше направена хируршка интервенција, оперкулектомија, и ортодонскиот третман започна со влечење на првиот молар на кој беше поставен стандарден брекет со еластична лигатура прикачена на мобилниот апарат. Еден месец подоцна движењето на забот беше очигледно.

Introduction

Tooth eruption is a continuous process by which developing teeth move through the soft tissue, oral epithelium, jaw bones and overlying mucosa, to emerge in the oral cavity, contact the teeth of the opposing dental arch, and enable teeth functional position in mastication. Humans are diphyodonts, which means we have two sets of teeth during lifetime. The first set, the primary teeth, also called deciduous teeth, or baby teeth, start erupting at around six months of age. The primary teeth fall out and are replaced by second set, permanent teeth about six years of age. The tooth eruption occurs in three phases, pre-eruptive, eruptive and post-eruptive phase. The teeth eruption driving force is still unknown but is thought to be due to a combination of a few factors, which include signals originating from the dental follicle, root formation and elongation, which could drive the tooth in order to acquire space within the jaw and an occlusal force, aiding in eruption¹. Tooth development results from a complicated multistep interaction between the oral epithelium and the underlying mesenchymal tissue. Abnormal tissue interactions during tooth development may potentially result in ectopic tooth development and eruption. Tooth eruption occurs as a tooth moves from the developmental position to the functional position. It is a complex process that can be influenced by a number of general factors like genetics, nutrition, preterm birth, hormonal factors, various systemic

diseases and some local factors². Delayed eruption or impaction of permanent teeth is one of the severe problems that can occur during the mixed dentition period. An impacted tooth is one that fails to erupt into the dental arch within the expected time. The permanent teeth impaction usually occurs in the downward order of third molars, maxillary canine, mandibular premolars, mandibular canine, maxillary premolars, maxillary central incisors, and mandibular second molars³. These conditions can occur in any permanent tooth, but the incidence of delayed eruption of the permanent first molars, especially maxillary permanent first molars, is very low. Permanent first molars, known as the “key teeth” in occlusion, are very important as guide to the correct position of the teeth in the dental arch. The eruption of the first and second permanent molars is especially significant for the coordination of facial growth, and for providing sufficient occlusal support for undisturbed mastication. There are many studies of impaction in the literature but only a few cases involving impacted permanent first molars. The impaction of permanent first and second molars is uncommon, with prevalence rates of 0.08% for the second maxillary molar and less than 0.01% for the first maxillary molar. Although, the impaction of mandibular second molars, given that its incidence is 0.03 to 0.21%, is a rare complication in tooth eruption. It has been detected more often in the unilateral form than in the bilateral one and is

more common in the mandible than in the maxilla. Several systemic and local factors are related to the cause of this anomaly. Impaction may result from local causes, such as malocclusion disturbances of the primary dentition, the position of the neighbouring teeth, supernumerary teeth, cysts, and odontoma⁴⁻⁶. Tooth retention has been attributed to an alteration of the dental follicle, which is unable to initiate the metabolic processes leading to bone resorption and eruption⁷. Roots develop completely even when the tooth cannot erupt because root formation seems to be unrelated to the eruption process. Retention may be related to ankylosis, which is probably due to a localised alteration of the periodontal ligament, but it has not yet been determined whether impairment of the eruptive mechanism occurs before or after ankylosis. Based on Winter's classification systems, impacted molars can be classified as vertical, distoangular, mesioangular, or horizontal in position according to tooth angulation. The occlusal plane can be used as a reference to check the depth of the impacted molars⁸. 2D and 3D radiographs are more than necessary for diagnosis and treatment planning of impacted teeth. Cases with impaction of more than one tooth are indication for CBCT⁹. Multiple impacted teeth are rare condition and usually present in some syndromes. Multiple impacted teeth with no obvious aetiology is rare dental anomaly. In literature, few reports are related to multiple impacted teeth with no known aetiology¹⁰. Complex-

ity of the treatment varies widely, so management is a big challenge and needs a multidisciplinary specialist approach. Treatment of impacted permanent molar consist of its surgical exposure and removal of any possible barrier¹¹. Orthodontic treatment is necessary in the event of abnormal positioning of the tooth, malocclusion, lack of space in the dental arch, or if spontaneous eruption is not expected. Orthodontic correction or prosthetic replacement of the missing tooth are often required. It is essential to diagnose and treat the impacted permanent molars as early as possible because treatment at a later stage is usually more complicated due to the tendency of malocclusion to increase with time and decrease the ability of remaining dentition to adjust¹². We report a very rare case with multiple teeth impaction where there was impaction of the maxillary first permanent molar, impaction of both maxillary second premolars and impaction of all, maxillary and mandibular permanent second molars. This condition compromise masticatory function. Unilateral mastication also compromise temporomandibular joint (TMJ).

The aim of this case-report was to present orthodontic treatment by Schwartz removable appliance in a patient with maxillary left-side impaction of the second premolar, first molar and second molar. Due to the low prevalence of impaction of the first and second permanent molars, there is a lack of uniformity in the management of these impact-

ed teeth, and published reports are mostly based on case reports with mesially inclined molars. In general, treatment options depend on the age of the patient as one of the key factors, severity of impaction, bone anatomy and position of vital structures, the amount of space available, oral health, type of malocclusion, patient motivation and opinion, as well as patient-related circumstances (finances). Cooperation between different specialties (orthodontists, oral surgeons and paediatric dentists), provides the best, individual results for each patient.

Case report

Treatment objectives

The primary objectives in our treatment were:

- to create anchorage for the orthodontic traction and incorporation of the impacted first molar into the dental arch with good bone and periodontal support;
- to regain slightly more space for the impacted second premolar;
- to position the maxillary and mandibular second molars into the dental arch, and
- to provide functional position to all impacted teeth.

The other objectives were to establish a good occlusion, to obtain an optimal overbite-overjet relationship and to provide long-term retention, to enhance the health of the

periodontium, and most importantly to provide bilateral mastication.

Treatment diagnosis

A 12-year-old girl with a late mixed dentition was brought to our Clinic for orthodontic treatment one year ago. The chief complaint was the presence of problems during mastication on the left side due to delayed eruption of the posterior teeth. The patient had no complain of pain, no signs of infection and had a good oral hygiene. Clinical examination revealed normodivergent face and presence of good facial balance in all proportions. Intraoral clinical examination revealed maxillary, unilateral, left-side absence in the oral cavity of the permanent second premolar, first molar and second molar and right-side absence in the oral cavity of the second premolar and second molar. Furthermore, the right and left mandibular second molars were also absent. The mandibular midline was shifted due to hypodontia of the mandibular central incisor. There was a space deficiency for teeth alignment. The patient revealed a limited mouth opening, microstomia. The occlusal examination noted a right-side Angle Class II, OJ was 3 mm and OB 5 mm. There was anterior deep bite and crossbite of the right permanent first molar and primary first molar (Fig. 1 a, b, c, d, e).

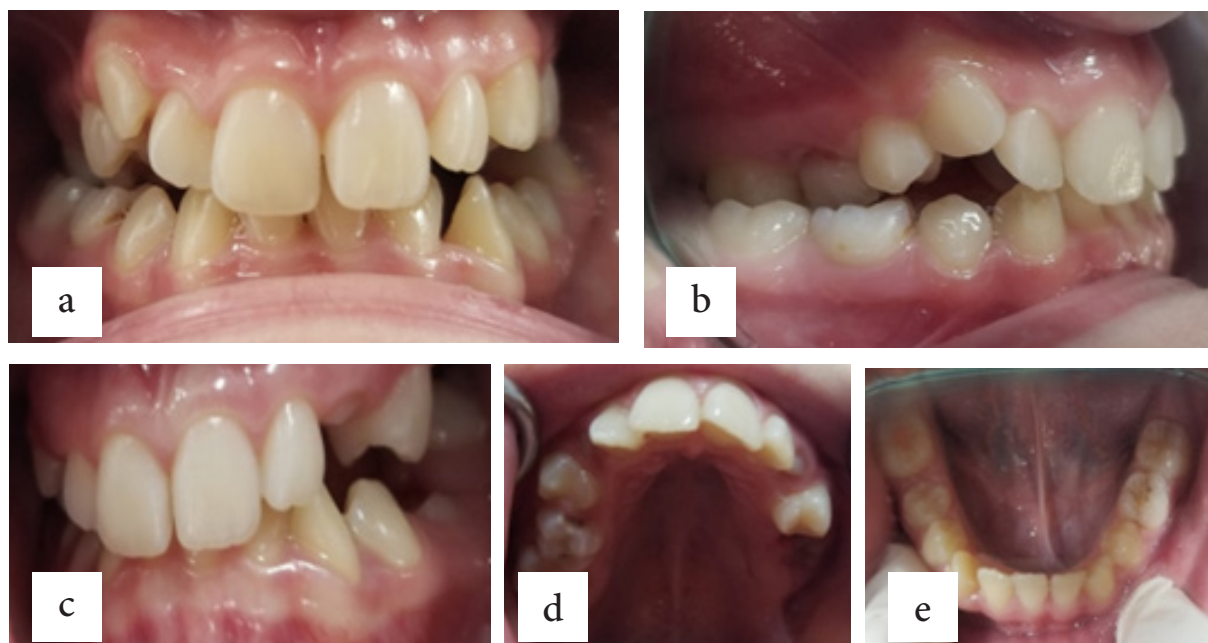


Figure 1. Intraoral clinical examination of a 12-year-old patient: a) Frontal view in occlusion and shifted mandibular midline, b) Cross bite of the right permanent first molar and primary first molar, and right-side Angle Class II, c) Left-side view, d) Upper occlusal view of the maxilla with left-side absence of permanent second premolar, first molar and second molar, e) hypodontia of the left mandibular permanent central incisor.

The panoramic radiograph revealed that all teeth were present (excluding the third molars and mandibular left central incisor). Hypodontia of the left mandibular central incisor was obvious. The left-side maxillary permanent second premolar, first molar and second molar were impacted. Furthermore, there was impaction and transposition of the right-side maxillary second premolar and impaction of all, maxillary and mandibular second molars and therefore, delayed teeth eruption to the dental arch. The panoramic radiograph revealed that the left-side second premolar and first molar posture were mesioangular and the position of the right-side second premolar was almost horizontal (Fig. 2).

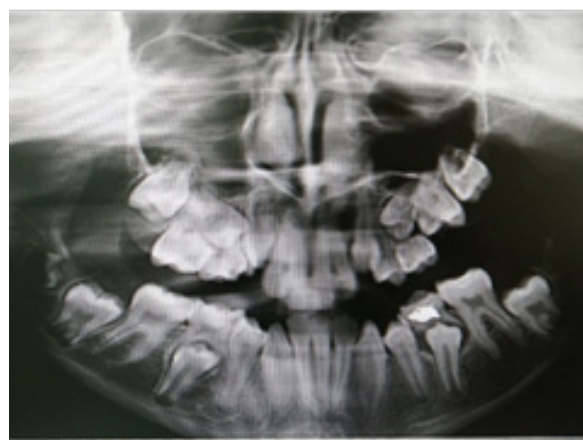

Figure 2. Panoramic radiograph of a 12-year-old patient before treatment

A CBCT was prescribed at this stage due to the impaction of many teeth. The CBCT showed areas with partial absence of alveolar bone and periodontal ligament on labial side of the left-side maxillary and mandibular first molars. Extrusion of the left mandibular first molar was notable due to absence of its antagonist and unilateral mastication (Fig. 3 a, b).

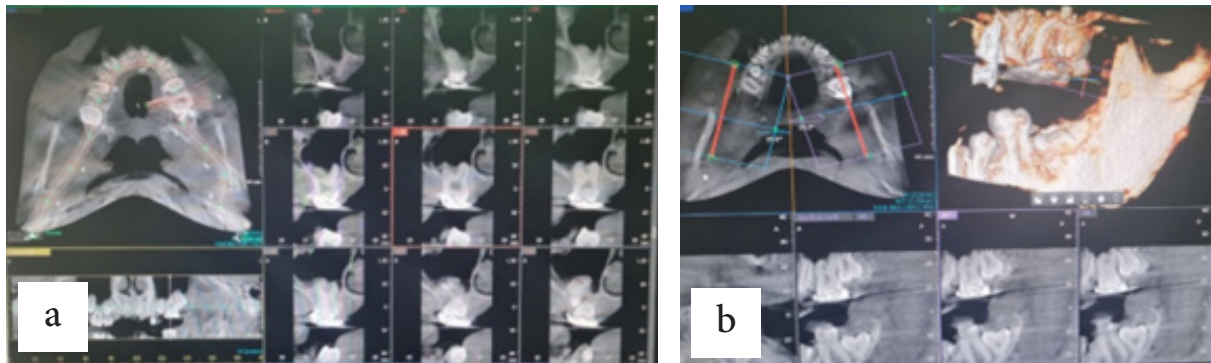


Figure 3. CBCT radiograph of a 12-year-old patient before treatment: a) Occlusal view of upper dental arch and labial view of partial absence of alveolar bone and periodontal ligament of the left-side maxillary and mandibular first molar, b) Notable extrusion of the left mandibular first molar due to absence of antagonist (maxillary first molar) and unilateral mastication.

Treatment plan

In the presented case we used Schwartz removable appliance for the traction of the left upper first molar and expansion of the maxilla and mandibula. Based on the patient's symptoms, extraoral and intraoral examination, as well as on panoramic radiograph and CBCT analysis, our treatment plan included:

- consultation with an oral surgeon about operculectomy of the impacted left-side maxillary first molar;
- intervention, surgical removal of the mucosa tissue of the occlu-

sal surface of the first permanent maxillary molar was done and then we monitored/observed the impacted tooth until the spontaneous eruption occurred;

- in our case eruption did not occur, and hence we assisted the eruption of the impacted teeth by orthodontic traction.

The initial therapy had started with wearing mobile appliance one year ago. A standard molar bracket was bonded three days after operculectomy, so we started positioning the tooth in the dental arch (Fig. 4 a, b).

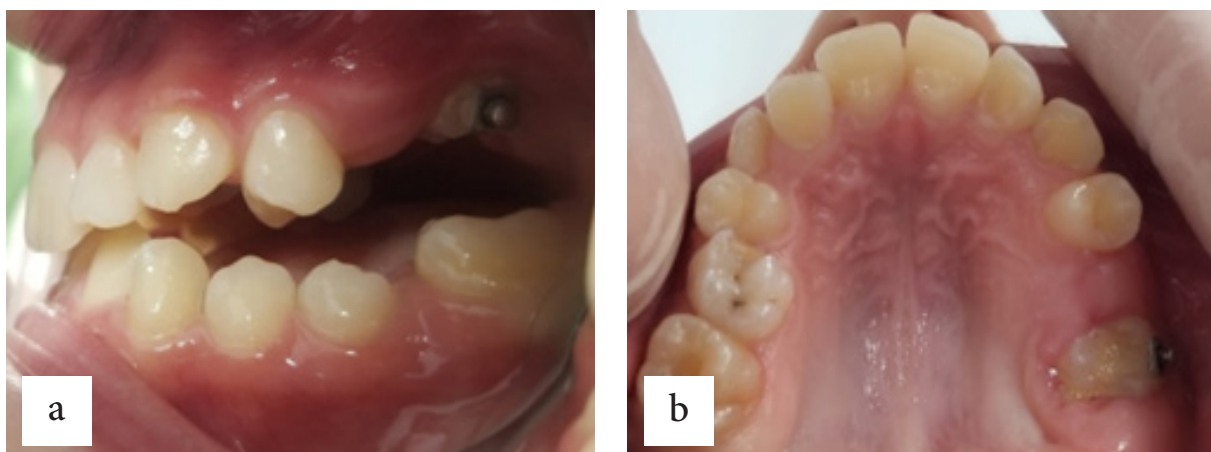


Figure 4. a) Standard molar bracket bonded three days after operculectomy b) Occlusal view

The traction of the first molar was with elastic ligature attached to the mobile appliance. Furthermore, the

orthodontic treatment in mandibula as in maxilla continued by their expansion (Fig. 5 a, b, c, d).

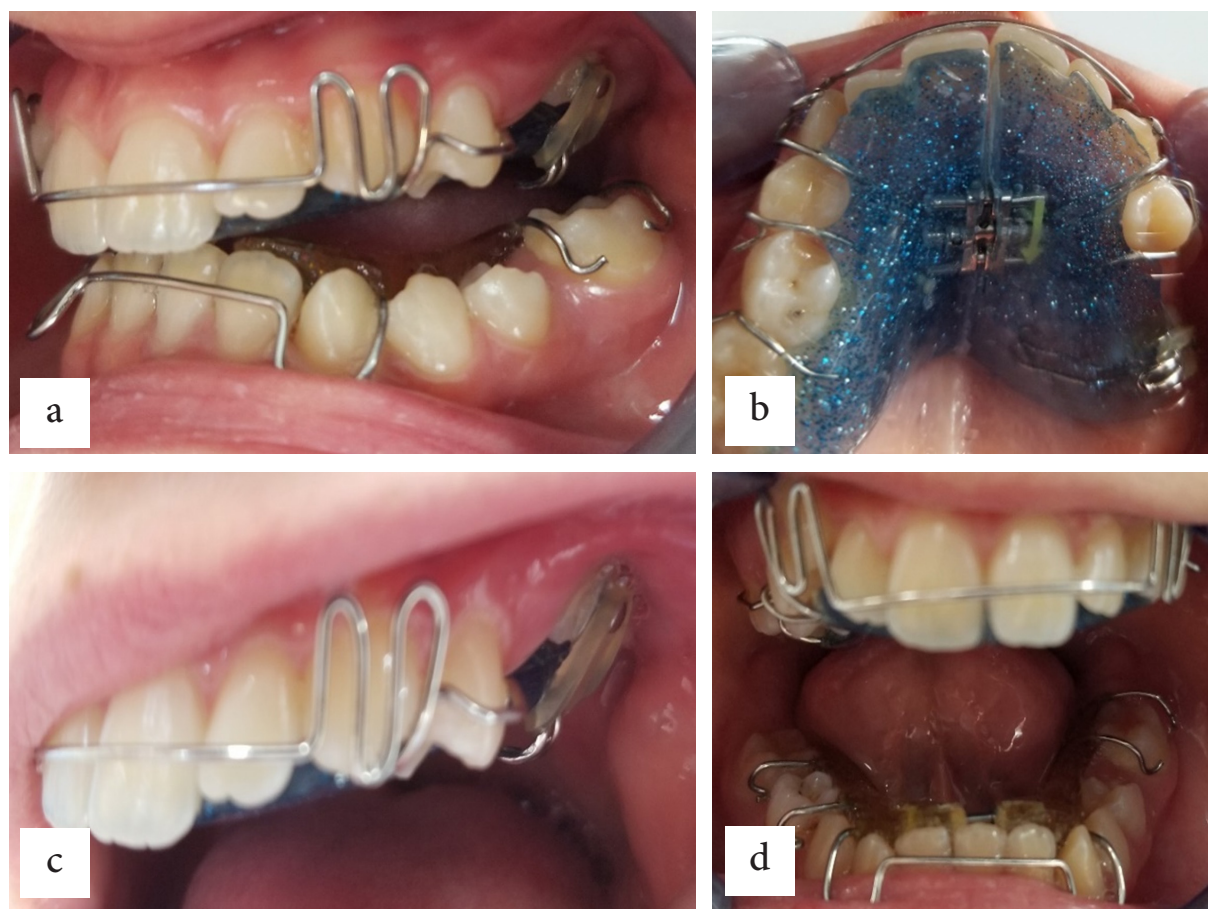


Figure 5. a) Removable Schwartz appliance with expansion screw in maxilla and mandibula, b) Occlusal view of maxillary appliance, c) Traction of the first molar with elastic ligature attached to the mobile appliance, d) Expansion of the mandibula by turning the screw.

One month later, the tooth movement was obvious, the upper first molar emerged from the gingiva and reached a more occlusal position by traction. The molar was further extruded. At 10-month follow-up, the extrusion of the left maxillary molar continued, remained vital and responded normally to mobility and sensitivity with a good width of attached gingiva.

Discussion

Tooth eruption is the axial movement of the tooth from its position in the bone to its final functional occlusion in the oral cavity and it is often used to indicate the moment of emergence of the tooth into the oral cavity¹³. The normal eruption of deciduous and permanent teeth into the oral cavity occurs over a broad chronologic age range. It can be influenced also by racial, ethnic, sexual and individual factors¹⁴. There are numerous eruptions regulating

molecules having similar and overlapping functions, which ensures that even the absence of a single factor does not interrupt the event of eruption. EGF, EGF-R, CSF-1, CSF-1R, IL-1, IL-1R, c-Fos, NF- κ B, MCP-1, TGF- β 1, PTHrP, Cbfa-1, OPG, RANK/RANKL are the major tooth eruption molecules. Majority of the eruption molecules reside in the dental follicle with few in the Stellate reticulum¹⁵. Some genetic disorders may be responsible for abnormalities in the eruption. Significant deviations from accepted norms of eruption sequence are often observed in clinical practice. Premature eruption has been noted but delayed tooth eruption is the most commonly encountered¹⁶. In normal eruption scenario, permanent teeth erupt eventually and replace their primary predecessors. However, some teeth fail to erupt. Most of these unerupted teeth are deviated or angulated aberrantly and eventually lose their potential to erupt and are referred to as impacted teeth. Epidemiological studies have reported dental impactions to affect 25 to 50% of human population¹⁴. Impaction of teeth can result from biomechanical impediments, crowding and malpositioning of adjacent teeth, previous dento-alveolar trauma, insufficient maxillofacial skeletal development, thickened mucosal and osseous tissues, eruption disturbances, indirect effects of cysts or neoplasms¹⁷. Impaction of a single tooth is a commonly observed clinical finding but impaction of multiple teeth is uncommon. Therefore, only a few cases of non-syndrome

multiple impacted teeth were reported in literature¹⁸⁻²¹. In those studies, the predominant explanation was that some physical barrier led to impaction and non-eruption of teeth²². Multiple teeth impaction is often associated with multiple syndromes such as Cleidocranial dysplasia, Gardner's syndrome, Yunis-Varon syndrome, Gorlin-Sedano syndrome²³. It is also common in endocrine disorders such as hypothyroidism, hypopituitarism, hypoparathyroidism. Metabolic disorders like vitamin D deficiency are also associated with impacted teeth. Our patient was with multiple teeth impaction, but no features of any disorder or syndrome were diagnosed. Further investigation and medical history of the patient showed no signs of metabolic disorders like vitamin D deficiency. Impacted teeth are those which are prevented from eruption by some physical barrier in their path of eruption. In our case, it seems that there was no local factor leading to multiple impactions of the permanent teeth. The oral soft tissues in our case were unremarkable and histopathological evaluations of gingivae were normal. The clinical and radiographic examinations of our case revealed relatively normal jaws and teeth. Delayed or arrested eruption was probably caused by lacking of eruptive force due to either general, neurogenic or mucosal and bone disorder. This was a case of primary failure of tooth eruption with no other systemic involvement. Candidate genes for primary failure of eruption would be the molecules that function solely

in the pre-eruptive phase and are expressed in cells of the dental follicle and surrounding structures. Hence, it is likely that genes like CSF-1, NFB, and c-fos are the genes responsible for the eruption defect and hypodontia²⁴. Duration and results of treatment in less frequent cases of multiple impactions are a major concern when compared to more frequent single impaction cases. Multidisciplinary approach would be the appropriate choice as treatment involves aesthetics, functional, and oral health problems. In case of unerupted teeth, orthodontic extrusions should be attempted²⁵. Obtaining stable results along with enhanced aesthetics, oral health, and the most important function, mastication, are the objective of our treatment.

Conclusion

The appearance of simultaneous multiple impactions of permanent teeth can be observed in both sexes with a healthy systemic condition, without any symptoms of any syndrome. These non-syndromic cases of multiple impactions are very rare. Impaction of the maxillary first molar and maxillary and mandibular second permanent molars does not occur frequently. Therefore, it is important to make an early diagnosis in order to start treatment at an optimal time, since masticatory function is compromised as in the reported case. The decision on how to manage orthodontic treatment is individual and based on more general factors such as age, psychologi-

cal profile of the child, position of the affected teeth, financial situation. These patients require a multidisciplinary approach to guide “eruption” of the teeth. The listed reasons show that the treatment of more impacted teeth in children is a real challenge, as is the particular case.

References

1. Massler M, Shour I. Studies in tooth development: theories of eruption. *American Journal of Orthodontics and Oral Surgery*. 1941; 27:552-576.
2. Marks SCJr & Schroeder H E. Tooth eruption: theories and facts. *The Anatomical record* 1996; 245(2): 374–393.
3. Peterson LJ, Ellis E, Hupp JR, and Tucker MR. Principles of management of impacted teeth. Eds. *Contemporary Oral and Maxillofacial Surgery*, Mosby, Maryland Heights, Missouri. 1998;215-248.
4. Grover PS, Lorton L. The incidence of unerupted permanent teeth and related clinical cases. *Oral Surg Oral Med Oral Pathol*. 1985 Apr;59(4):420-5. doi: 10.1016/0030-4220(85)90070-2.
5. Brady J. Familial primary failure of eruption of permanent teeth. *Br J Orthod*. 1990; 17(2):109-113. doi: 10.1179/bjo.17.2.109.
6. Oliver RG, Richmond S, Hunter B. Submerged permanent molars: four case reports. *Br Dent J*. 1986;160(4):128-30. doi:

- 10.1038/sj.bdj.4805789.
7. Raghoobar GM, Boering G, Vis-sink A, Stegenga B. Eruption disturbances of permanent molars: a review. *J Oral Pathol Med.* 1991; 20(4):159-66. doi: 10.1111/j.1600-0714.1991.tb00913.x.
 8. Mariano RC, Mariano Lde C, de Melo WM. Deep impacted mandibular second molar: a case report. *Quintessence Int.* 2006;37(10):773-6.
 9. Magnusson C, Kjellberg H. Impaction and retention of second molars: diagnosis, treatment and outcome. A retrospective follow-up study. *Angle Orthod.* 2009; 79(3):422-7. doi: 10.2319/021908-97.1.
 10. Guruprasad Y, Naik RM. Multiple impacted teeth in a non-syndromic patient. *SRM J Res Dent Sci* 2012; 3:279-80.
 11. Raghoobar GM, Boering G, Vis-sink A. Clinical, radiographic and histological characteristics of secondary retention of permanent molars. *Journal of dentistry* 1991; 19(3), 164-170.
 12. Jacobs SG. The surgical exposure of teeth--simplest, safest and best. *Australian orthodontic journal.* 1987;10(1), 5-11.
 13. Nlla C M. The development of the permanent teeth. *J Dent Child.* 1960; 27, 254-66.
 14. Suri L, Gagari E, Vastardis H. Delayed tooth eruption: pathogenesis, diagnosis, and treatment. A literature reviews. *American journal of orthodontics and dentofacial orthopaedics: official publication of the American Association of Orthodontists, its constituent societies, and the American Board of Orthodontics.* 2004; 126(4), 432-445.
 15. Sujatha G, Sivapathasundharam B, Sivakumar G, Nalin-kumar S, Ramasamy M, Prasad TS. Idiopathic multiple impacted unerupted teeth: Case report and discussion. *Journal of oral and maxillofacial pathology: JOMFP* 2012;16(1): 125-127.
 16. Huber KL, Suri L, Taneja P. Eruption disturbances of the maxillary incisors: a literature review. *The Journal of clinical paediatric dentistry* 2008; 32(3), 221-230.
 17. Bayar GR, Ortakoglu K, Sen-cimen M. Multiple impacted teeth: report of 3 cases. *European journal of dentistry,* 2008; 2(1), 73-78.
 18. Guruprasad Y, Naik RM. Multiple impacted teeth in a non-syndromic patient. *SRM J Res Dent Sci* 2012; 3:279-280.
 19. Yalcin S, Gurbuzer B. Multiple impacted teeth in the maxilla. *Oral Surg Oral Med Oral Pathol.* 1993;76(1):130. doi: 10.1016/0030-4220(93)90310-z.
 20. Sivakumar A, Valiathan A, Gandhi S, Mohandas AA. Idiopathic failure of eruption of multiple permanent teeth: report of 2 adults with a highlight on molecular biology. *Am J Orthod Dentofacial Or-*

- thop. 2007;132(5):687-92. doi: 10.1016/j.ajodo.2006.04.034..
21. Tanaka E, Kawazoe A, Nakamura S, Ito G, Hirose N, Tanne Y, et al. An adolescent patient with multiple impacted teeth. *Angle Orthod.* 2008; 78(6):1110-8. doi: 10.2319/121007-581.1.
 22. Sujatha G, Sivapathasundharam B, Sivakumar G, Nalin-kumar S, Ramasamy M, Prasad TS. Idiopathic multiple impacted unerupted teeth: Case report and discussion. *J Oral Maxillo-fac Pathol.* 2012; 16(1):125-7. doi: 10.4103/0973-029X.92989.
 23. Chodirker BN, Chudley AE, Toffler MA, Reed MH. Zimmerman-Laband syndrome and profound mental retardation. *Am J Med Genet.* 1986; 25(3):543-547. doi: 10.1002/ajmg.1320250317.
 24. Wise GE, Frazier-Bowers S, D'Souza RN. Cellular, molecular, and genetic determinants of tooth eruption. *Crit Rev Oral Biol Med.* 2002;13(4):323-34. doi: 10.1177/154411130201300403.
 25. Karsten Al. The orthodontic treatment of impacted teeth, 2nd edition. *European Journal of Orthodontics* 2007; 29(6): 662.